

**Hitachi Real-time Tissue
Elastography:**

**Publications & International
Communications**

Clinical Abstracts



HI-RTE

Hitachi Real-time Tissue Elastography

**Hitachi Real-time Tissue Elastography
Other Applications**

ELASTOGRAPHIC ULTRASOUND QUANTITATIVE ANALYSIS COMBINED WITH HIGH FREQUENCY IMAGING FOR CHARACTERIZATION OF BENIGN AND MALIGNANT SKIN LESIONS

Presenter: Bahar Dasgeb

Abstract Co-Authors: Eliot Siegel

PURPOSE

The purpose of this study was to investigate the use of ultra-high frequency sonography and quantitative ultrasound elastography for a variety of malignant and non-malignant skin lesions.

METHOD AND MATERIALS

Forty patients with proliferative malignant neoplasms or benign skin lesions were imaged utilizing an ultra-high frequency sonography system. Elastographic properties of these lesions were also assessed. Malignant tumors included squamous cell carcinoma, basal cell carcinoma, and melanoma. Benign lesions included benign cephalic histiocytosis, dermatofibroma, lipoma, intradermal nevus, angioma, trichoepithelioma, and others. Diagnosis was confirmed histopathologically.

The physical interaction of the tissue with ultrasonic waves in the 14 to 16 MHz range was quantified using a color coding schema to reflect its physical elasticity. The ratio of elasticity between adjacent normal skin and each skin lesion was calculated. Histopathological findings including the size, extent, and depth of the lesions were recorded.

RESULTS

Cystic lesions demonstrated high levels of elasticity while malignant lesions were relatively "hard" with a very low level of elasticity. The ratio of normal skin to the various skin lesions ranged from 0.04 to 0.3 for cystic skin lesions, 0.4 to 5.0 for benign proliferative lesions such as intradermal nevi or benign histiocytosis, and a ratio above 10.0 was characteristically seen in malignant lesions.

CONCLUSION

High frequency ultrasound imaging and elastographic analysis visualized and quantified the elasticity of the skin and superficial soft tissue lesions. Malignant lesions were significantly less elastic (harder physically) than benign ones. We believe that this may be related to a higher density of DNA in the proliferative and compact S phase for these lesions but other characteristics, such as vascularity and compromised integrity of interstitial fibrous tissue in the chemo-immune environment of malignant skin lesions may also play a substantial role in determining their elastographic characteristics. In addition, the ratio of elasticity of the lesions to surrounding tissues was found to strongly correlate with the proliferative state of the tumor based on histopathology.

CLINICAL RELEVANCE/APPLICATION

High frequency ultrasound with ultrasound elastography successfully delineated the extent of and was able to provide quantitative differentiation among a variety of benign and malignant lesions.

Radiological Society of North America 95th Scientific Assembly and Annual Meeting November 29th – December 4th, 2009, Chicago, USA

VIBROGRAPHY AND FREE HAND ELASTOGRAPHY FOR RESECTION OF GLIOMAS AND OTHER BRAIN TUMORS.

M Scholz, S Möller, J Thissen, C Löhnert, P Spangenberg, A Harders.
Neurosurgery Department, Ruhr-University Bochum, GERMANY.

Aims: The aim of this study was to determine whether elastography, an ultrasound-based real-time

strain imaging method for registering the elastic properties of tissue, can be used in brain tumor surgery and especially for resection of gliomas.

Methods: From 2004 to 2008, elastography was first applied in 63 cases in our clinic in vibrography mode [1,2]. The real-time vibrography system consisted of a conventional ultrasound system (Siemens Sonoline Omnia) with a custom-designed RF interface and a 6.5MHz endocavity curved array (Siemens 6.5EC10). The RF data were digitized using a 50MHz, 12-bit PCI analog/digital (A/D) converter for real-time or offline processing. Static compression was replaced by low-frequency axial vibration of the probe. A special applicator equipped with a stepping motor moved the ultrasonic probe and produced a low frequency mechanical vibration of ~ 5–10Hz with a vibration amplitude of 0.3mm and slight preliminary compression (total <1mm). The maximum application time was 60sec. A pneumatic holding device (Unitrac, Aesculap, Tuttlingen, Germany) was used. Since April, 2008, elastography was used in 10 glioma patients in a free hand fashion during brain tumor surgery. A conventional ultrasound system (Hitachi, EUB 8500HV, Wiesbaden, Germany) with a custom designed radio frequency (rf) interface was used. Ultrasound-rf-data was acquired with an endocavity phased array (5–9MHz; Hitachi, EUP-V53W, Wiesbaden, Germany). The study was conducted with the approval of the Ethics Commission of the Ruhr-University Bochum (No.: 3139-08). Elastography was performed immediately after dura opening (Figure 1). MR-neuro-navigation was used to precisely determine the position of the ultrasound probe.

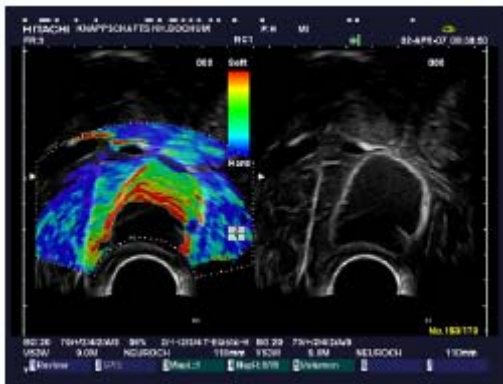


Figure 1: Free hand elastography in a cystic intracerebral metastasis.

After resection of the tumor, elastography and conventional sonography was again applied to localize residual tumor. This was done several times until the neurosurgeon stated that the resection was finished. Then the resection cave was additionally controlled with elastography by introducing the small probe. If residual tumor could be visualized, further resection was performed. Biopsies were done in areas of unknown histology. An early postoperative MRI was done.

Results: With the free hand method, detection of tumors was possible in all cases. Different relative tumor strains could be detected. Especially in huge gliomas, control of tumor resection is difficult because the neurosurgeon needs healthy brain tissue to compare to the tumor tissue. Two residual tumors (one oligoastrocytoma and one recurring glioblastoma) could not be seen with conventional ultrasound, but could be seen with elastography and could be successfully resected with microsurgery. Average sonographic application time was between 5–7.5 minutes.

Conclusion: These findings indicate that free hand elastography is feasible in surgery of gliomas for control of resection and may have numerous potential applications in neurosurgery if further improvements are performed. Application of this method can be taught and performed faster in comparison to concurring methods.

References:

- [1] Scholz M, Fricke B, Mönning P, Brendel B, Schmieder K, Siebers S, Düring von M, Ermert H, Harders A, Vibrography: First experimental results in swine brains. *Min Invas Neurosurg*, 47: 1–7, 2004.
- [2] Scholz M, Noack V, Pechlivanis I, Engelhardt M, Fricke B, Linstedt U, Brendel B, Schmieder K, Ermert H, Harders A, Vibrography during tumor neurosurgery, *J Ultrasound Med*, 24 (7): 985–92, 2005.

Eighth International Conference on the Ultrasonic Measurement and Imaging of Tissue Elasticity, September 14 – 17, 2009, Vlissingen, The Netherlands

ELASTOGRAPHIC DIAGNOSIS OF AMELANOTIC SKIN LESIONS

Dr Michiko Nakajima, Dr Yoshio Kiyohara, Dr Masahito Taguchi, Dr Masayuki Kobayashi
Saitama Medical University, Japan

Objective: We examined to evaluate the diagnostic performance of real-time freehand elastography by using the extended combined autocorrelation method to differentiate benign from malignant amelanotic skin lesions. We used pathologic diagnosis as the reference standard.

Material and Methods: Studies were made on the 10 cases of benign skin tumors and 8 cases of malignancy. In conventional study, we used 13-6MHz linear transducer. First, B mode and color Doppler sonography was performed. On same day, we next obtained Elastography images as motion images. All elastographic imaging was performed with a 13-6(7.5MHz) linear transducer without the stabilizer. Follow TSUKUBA elastography score to a breast cancer, we assigned each image an elasticity score on a five point scores.

Score 1: The entire lesion was evenly shaded green.

Score 2a: The lesion shows mosaic of green and blue, and the thing of green predominance.

Score 2b: The lesion shows mosaic of green and blue, the thing of blue predominance.

Score 3: The central part of the hypoechoic lesion is blue and the peripheral part of the lesion is green.

Score 4: The entire lesion is blue.

Score 5: Both the entire lesion and its surrounding area are blue.

Results: Using elastography, almost malignant tumors changed deep blue and benign tumors even though hypervascular tumors were evenly shaded green or mosaic (green dominant).

Conclusion: It is useful for differential diagnosis of amelanotic skin lesions to use elastography.

12th World Congress of the World Federation for Ultrasound in Medicine and Biology, 30th August – 3rd September 2009, Sydney, Australia

USEFULNESS OF ULTRASONOGRAPHIC ELASTOGRAPHY FOR EVALUATION OF VENOUS THROMBOEMBOLISM

Kazuhiro Shimizu, Takanobu Tomaru,
Cardiology Center, Toho University Sakura Hospital, Sakura

We evaluated usefulness of ultrasonography elastography (USEG) for diagnosis of deep venous thrombosis (DVT).

Methods: The 189 cases were divided into 5 groups according to the time from onset: A: Within 1 week (W) (n=45), B: 1 W to 1 month (M) (n=74), C: 1M to 3 M (n=31), D: 3M to 12 M (n=19), E: More than 12M (n=20). USEG (Hitachi) can evaluate hardness of thrombus by color images. By USEG, hardness of thrombus was divided into 3 groups (soft or none: red, medium: green, hard: blue). Within 1 W, USEG demonstrated red color in 3 and green color in 17 cases.

Results: After 12 M, USEG demonstrated red or green color in few cases. Red color was present until 1 M, and number of cases with green color decreased from 1 to 3 M. Blue color was detected from 1W to more than 12M, but peak period was 1W to 1M. Blue color represents with old thrombus and red with fresh one. C-reactive protein (CRP) was greater in green group than in blue (4.25±6.23 microgram per ml vs 1.41 and standard deviation 2.23 microgram per ml, P=0.05). D-Dimer was greater in green group than in blue (14.00±13.17 microgram per ml vs 11.31±19.44 microgram per ml, P=0.05).

In conclusion, USEG was very useful for evaluation of characteristics of VTE, and could differentiate fresh thrombus from old and hard one. D-Dimer or CRP may be associated with fresh thrombus.

Circulation Journal Vol 73, Suppl 1, 2009

ULTRASOUND ELASTICITY IMAGING CAN DETECT HIGH RISK PATIENTS WITH DEEP VEIN THROMBOSIS WHO RESULTS IN PULMONARY EMBOLISM

Hiroyasu Kato, Masami Nishino, Masahiko Hara, Takahiro Yoshimura, Daisuke Nakamura, Yasuharu Lee, Shimpei Nakatani, Akihito Hashimoto, Kiyoshi Yamagami, Yasuyuki Egami, Ryu Shutta, Hitoshi Yamaguchi, Jun Tanouchi, Yoshio Yamada
Division of Cardiology, Osaka Rosai Hospital, Sakai

Ultrasound elasticity imaging (UEI) is a technology for imaging tissue hardness. Deep vein thrombosis (DVT) undergo progressive hardening. We examined whether UEI can detect high risk patients with DVT who result in pulmonary embolism(PE). UEI were performed with EUB 8500 (Hitachi Medical Corporation) in 20 consecutive patients with DVT. Using UEI, we analyzed elasticity score, strain value and strain ratio. In addition, we evaluated occurrence of PE using contrast enhanced computer tomographic angiography (CTA) and lung perfusion scintigram (PS). We divided our patients into PE group and non-PE group and compared ultrasound parameters and incidence of dyslipidemia, diabetes mellitus and hypertension. Twelve patients (60%) were diagnosed as PE. Strain value of PE group was significantly lower than that of non-PE group (table). UEI is effective to distinguish high risk patients with DVT.

	PE group(n=12)	Non PE group(n=8)	p value
Age	67±16	67±16	n.s.
Male	4(33%)	3(38%)	n.s.
Diabetes Mellitus	2(17%)	1(13%)	n.s.
Hypertension	4(33%)	2(25%)	n.s.
Dyslipidemia	7(58%)	5(65%)	n.s.
Elasticity Score	2.2±1.0	2.1±1.3	n.s.
Strain Value	0.43±0.08	0.48±0.22	p<0.05
Strain Ratio	6.3±12.2	20.0±25.8	n.s.

Circulation Journal Vol 73, Suppl 1, 2009

AGING OF VENOUS THROMBOSIS - COMPARISON BETWEEN HISTOLOGICAL AND TISSUE ELASTICITY IMAGING

Kiyoko Uno, Akiko Tonomura, Makoto Yamakawa, Tomoko Ishizu, Yoshihiro Seo, Satoshi Honma, Tsuyoshi Shiina, Kazutaka Aonuma

Tissue elasticity imaging is a technology for imaging tissue hardness. Venous thrombus is known to be harder and stabilized as they mature. The aim of this study was to examine the diagnostic ability of ultrasound elastography for determining the age of venous thrombus by histological verification.

Methods. Experimental venous thrombi aging 2, 5, 7, 10 and 14 days were created in a rat model by ligation of infrarenal Vena cava. Thrombosed Vena cava were underwent examination by ultrasound elastography. In addition, histological evaluation of the thrombi was performed.

Results. As shown in figure, ultrasound elastography demonstrated a harder image correlated with the increasing of fibroblast and collagen production in the clots, and recanalisation site showed a soft image.

Conclusion. Ultrasound elastography is useful in determining the age of venous thrombus.

Circulation Journal Vol 72, Suppl 1, 2008

ELASTOGRAPHIC AND COLOR DOPPLER DIAGNOSIS OF SKIN TUMORS

Dr Nakajima, Saitama Medical University

Purpose: To evaluate the diagnostic performance of real-time freehand elastography by using the extended combined autocorrelation method (CAM) and color power) Doppler sonography to differentiate benign from malignant skin lesions.

Method and materials: Studies were made on the 40 cases of benign skin tumors and 40 cases of malignancy. In Elastographic study, we used EUB 8500 system. During our conventional examination, we obtained B-mode images first, and then color Doppler US was performed. On the same day, we next obtained elasticity images as motion images. We assigned each image an elasticity score on a five point scores. Score 1: the entire lesion was evenly shaded green. Score 2a: the lesion shows mosaic of green and blue. and the thing of green predominance. Score 2b: the lesion shows mosaic of green and blue. and the thing of blue predominance. Score 3: The central part of the hypoechoic lesion is blue and the peripheral part of the lesion is green. Score 4: The entire lesion is blue. Score 5: Both the entire lesion and its surrounding area are blue. In color Doppler imaging, We classified 4 types. Type 1: color signal is not detected in the lesions. Type 2: Single vascular pole in the lesions is detected Type 3: A lot of straight internal vessels and branches are detected. Type 4: A lot of tortuous internal vessels and branches are detected. We used pathologic diagnosis as the reference standard.

Results: In color Doppler examination, 31 benign lesions were showed type 1 or 2, whereas the malignant tumors were showed type 3 or 4. But 9 benign lesions were showed type 3 or 4, namely they were hypervascular tumors as same as malignancy. In elastographic examination all benign lesions were showed score 1 or 2a and all malignant tumors were showed score 2b or above 2b. Moreover about within 2 cm malignant tumors(36 cases), they were all showed score 3,4 and 5.

Conclusion: It is useful for differential diagnosis of skin tumors to use elastography combined color Doppler sonography.

Clinical relevance/application: Elastography study is safety and can demonstrate eloquent areas of malignant skin tumors and this exam is recommended when the underlying cause of such a lesion is unclear.

Radiological Society of North America 93rd Scientific Assembly and Annual Meeting November 25th – 30th, 2007, Chicago, USA

ULTRASONIC ELASTOGRAPHY IMAGING OF DEEP VEIN THROMBOSIS

Kazuhiro Shimizu, Takanobu Tomaru, Keijiro Nakamura, Keiichi Hirano, Hirofumi Noike, Mao Takahashi, Takeshi Sakurai

Department of Cardiovascularcenter, Sakura Hospital, Toho University School of Medicine, Chiba

Background: Elastography is a unique ultrasonoic(US) technique invented by Hitachi Medical and Tsukuba University in Japan. This technique can provide the relative elasticity of substance in color images. Color images are graded according to the elasticity, and they change from blue for hard to red for soft. We applied this new technique to evaluate deep venous thrombosis (DVT) since 2004 using EUB 8500.

Aim: To evaluate the hardness of venous thrombus in the patients with DVT, and examine the course of thrombus.

Object: Acute or chronic 51 DVT were examined by this methods in our hospital since October 2004 to September 2006. Age is 66.5 ± 12 . 23 patients were male and 28 patients were female.

Results: 7 cases developed into PTE. 44 cases were DVT alone. In PTE case, 57.1% were green color imaging and 28.5% were blue. In non PTE case, 18.2% were green and 81.5% were blue.

Conclusion: green color imaging thrombus on elastography are more likely to develop into PTE. ($p=0.0239$) Blue color imaging thrombus are not likely to develop into PTE. ($p= 0.0021$)

Circulation Journal Vol 71 Suppl 1 PJ-709, 2007

APPLICATION OF ULTRASONIC ELASTOGRAPHY FOR EVALUATION OF DEEP VENOUS THROMBOSIS

K. Shimizu, K. Nakamura, T. Hirohashi, et al

Background: we strated to use ultrasonographic (US) elastography to evaluate hardness and color of thrombus in DVT patients. This new elastography technique was invented by Hitachi in 2003, and often used to evaluate elasticity for tumor of the breast in japan. Elasticity of thrombus was evaluated by compression US (elastography). Color images are graded from blue for hard to read for soft. We applied this new technology to evaluate DVT.

Aim: To evaluate the hardness of DVT, and examine the response of therapy by color.

Object: 11 had admitted in our hospital to treat DVT since Oct 2004 to Sept 2005. Age is 37 – 76 years old. Patient's background were various, cancer, pregnancy, CV catheter, long drive, etc

Methods: All patients had given heparin and warfarin and put a elastic stocking. Some patients had given urokinase by drip infusion from distal leg. Our using US system is HITACHI EUB-8500. In addition, some patients had done angioscopy (AS) to evaluate the thrombus.

Conclusion: We are able to observe the elasticity of DVT. 3 or 6 months later, 4 red-green color thrombus in elastography was already lost or diminished. 7 blue thrombus in elastography were existed yet. Ultrasonographic (US) elastography is a useful tool for evaluation of DVT. Color of thrombus may suggest us whether this thrombus have a possibility of dissolution or not.

Circulation Journal Vol 70 Suppl 1 PE-623, 2006

ELASTOGRAPHIC DIAGNOSIS OF SKIN TUMORS

Michiko Nakajima, Masao Shimizu, Osamu Kishino, Rieko Igarashi, Kimie Takeuchi, Yoshio Kiyohara*, Kazuhide Nanri** Clinical Laboratory Medicine, Saitama Medical University, Saitama, *Dermatology, ** Clinical Laboratory, Shizuoka Prefectural Cancer Center, Shizuoka, Japan.)

Aims:

To determine whether skin tumors were malignancy or not, we used Elastography.

Materials and methods:

Materials: Thirty cases of benign skin tumors (atheroma, nevus, lipoma, hemangioma, granuloma) and 32 cases of malignant skin tumors(squamous cell carcinoma, basal cell carcinoma, malignant melanoma, intransit metastasis of malignant melanoma and malignant lymphoma).

Methods: After we used gray scale sonography, and color Doppler sonography, we examined elastography using HITACHI EUB 8500. In this elastography, according to elastic coefficient is increased, the color imaging changes red, green to blue.

Results:

Twenty eight cases of benign tumors were seen green and 2 benign tumors were seen mosaic (red-green-blue). Twenty seven malignant tumors were seen blue or deep blue. Five malignant tumors were seen mosaic but blue area was dominant. We observed that the red area was fusional area or vessels using gray scale sonography and color Doppler sonography.

Conclusions:

It is useful for differential diagnosis of skin tumors using elastography.

XIXth Congress of European Federation of Societies for Ultrasound in Medicine and Biology, September 15th – 18th, 2006, Bologna, Italy.
