

**Hitachi Real-time Tissue
Elastography:**

**Publications & International
Communications**

Clinical Abstracts



HI-RTE

Hitachi Real-time Tissue Elastography

Hitachi Real-time Tissue Elastography for Urological Applications

STATUS OF TRANSRECTAL ULTRASOUND IMAGING OF THE PROSTATE.

Aigner F, Mitterberger M, Rehder P, Pallwein L, Junker D, Horninger W, Frauscher F.
Department of Radiology, Medical University Innsbruck, Innsbruck, Austria.

Abstract

PURPOSE: To describe the current and new developments in transrectal ultrasound (US) imaging of the prostate.

PATIENTS AND METHODS: Grayscale imaging of the prostate is the standard method for diagnostic evaluation and biopsy guidance. Color Doppler (CD) imaging, including CD and power Doppler US, allows for detection of macrovascularity and may therefore be helpful for assessment of prostatic blood flow. The use of US microbubbles for CD imaging and new contrast-specific techniques enable assessment of prostate microvascularity associated with prostate cancer (PCa). Recently, real-time elastography has been introduced to improve detection of cancer based upon changes in tissue stiffness.

RESULTS: Contrast-enhanced CD imaging has shown to enable PCa detection by performing targeted biopsies into suspicious areas. Comparisons between systematic and contrast-enhanced targeted biopsies have shown that the targeted approach detects more cancers and cancers with higher Gleason scores with a reduced number of biopsy cores. New microbubble-specific US techniques can improve sensitivity and specificity of US imaging for PCa detection. Real-time elastography has been demonstrated to be useful for the detection of PCa, and may further improve PCa staging.

CONCLUSIONS: The new US techniques seem to have the potential to improve PCa detection, and also PCa grading and staging. As these diagnostic methods improve, the ultimate hope is to eliminate biopsy in patients without cancer.

J Endourol. 2010 May;24(5):685-91.

REAL-TIME BALLOON INFLATION ELASTOGRAPHY FOR PROSTATE CANCER DETECTION AND INITIAL EVALUATION OF CLINICOPATHOLOGIC ANALYSIS

Masakazu Tsutsumi¹, Tomoaki Miyagawa¹, Takeshi Matsumura², Tsuyoshi Endo³, Syuya Kandori¹, Tatsuro Shimokama⁴ and Satoru Ishikawa¹

¹ Department of Urology, Hitachi General Hospital, 2-1-1 Johnan-cho, Hitachi, Ibaraki 317-0077, Japan.

² Ultrasound Systems Division, Hitachi Medical Corporation, Kashiwa, Japan.

³ Department of Urology, Tsukuba Medical Center Hospital, Tsukuba, Japan.

⁴ Department of Pathology, Nippon Steel Yawata Memorial Hospital, Kitakyushu, Japan.

OBJECTIVE. The use of elastography is limited for prostate cancer detection because of the difficulty in obtaining stable and reproducible images. To overcome these limitations, we developed a new technique called real-time balloon inflation elastography (RBIE); with RBIE, balloon inflation and deflation are used in place of manual compression. We present the accuracy and feasibility of the RBIE technique for detecting prostate cancer.

MATERIALS AND METHODS. The results of a pathologic analysis of 55 prostatectomy specimens were compared with elastographic moving images obtained at the time of biopsy of the prostate.

RESULTS. The RBIE technique generated stable and repeatable elastographic moving images. The percentage of images affected by artifact due to slippage in the compression plane was reduced to 1% using the RBIE method compared with 32% using the manual compression method. With regard to tumor location, elastographic moving images obtained using the RBIE technique were in complete agreement with clinicopathologic evaluation of tumor location in eight cases (15%), showed partial agreement in 43 cases (78%), and disagreed in four cases (7%). In three different regions of the prostate, 84% of anterior tumors, 85% of middle tumors, and 60% of posterior tumors were detected. The tumor detection rates by Gleason score were 60% in tumors with a Gleason score of 5 or 6, 73%

in tumors with a Gleason score of 7, 72% in tumors with a Gleason score of 8, and 74% in tumors with a Gleason score of 9 or 10.

CONCLUSION. The RBIE method improved the quality of elastographic moving images compared with the manual compression method. High-grade tumors and tumors of impalpable regions of the prostate were more frequently detected using RBIE. We conclude that RBIE is a promising method with which to detect prostate cancer.

AJR Am J Roentgenol. 2010 Jun;194(6):W471-6.

LIMITATIONS OF REAL-TIME ELASTOGRAPHY IN THE DETECTION OF PROSTATE CANCER. IMPORTANT FACTS FOR FUTURE STUDIES

Alexandre Pelzer, Julia Heinzelbecker, Matthias Kirchner, Philipp Stroebel, Stephan Maurice Michel

INTRODUCTION AND OBJECTIVES

Real-time sonoelastography (HI-RTE) has been proven capable to visualize prostate cancer (PCa) areas and therefore can be used for PCa detection. However, application and assessment of this novel technique has several limitations that are important to know for the design of future studies. We evaluated the role of HI-RTE limitations by applying this method to patients before undergoing radical retropubic prostatectomy (RRP) and comparing the results with whole mounted sections.

METHODS

In this study 800 prostate sectors with biopsy proven PCa scheduled for RRP were included and underwent HI-RTE by 2 investigators. HI-RTE was done by using a transrectal ultrasound probe (EUB-7500HV Hitachi medical systems with EUP-V53W probe). Local elastography findings were compared with histology. Areas suspicious for PCa were depicted and documented blinded to the pathological reports. RRP specimens were serially step sectioned and whole mounted after a modified Stanford protocol, tumour areas were marked by felt pen and each prostate was divided into 16 sectors. Areas suspicious for PCa were correlated with the corresponding whole mounted sections by sectors. HI-RTE images compared to whole-mounted sections were evaluated based on the reports on diagnostic findings. False negative as well as false positive results were evaluated and characterised.

RESULTS

Until now 50 specimens with 800 prostate sectors were evaluated. Mean PSA of PCa patients was 9.5 ng/ml with Gleason Scores in between 6-9. Mean examination time was 14 (6 to 25 minutes). The most common cause for false negative and false positive characterisation of prostate tissues with a significant influence on sensitivity and specificity of the results were large transitional zone volume, patients after transurethral resection of the prostate, prostate volumes of more than 80ccm, large calcification in the peripheral zone after prostatitis, multifocal tumors with tumordiameters of less than 3-5 mm, very large tumours capturing the whole prostate and patients not able to relax pelvic floor musculature. Furthermore initial acquisition of HI-RTE skills seems to be tremendously/highly/very important to receive reliable results.

CONCLUSIONS

HI-RTE is a sensitive imaging modality for the detection of PCa and furthermore proved to be a high-specific imaging modality for lesion characterisation. However, patient selection and the knowledge of the technique's limitations are very important for to receive reliable results with high sensitivity and specificity in PCa detection.

The Journal of Urology April 2010 (Vol. 183, Issue 4, Supplement, Page e780)

11-06-10

REAL-TIME ELASTOGRAPHY COMPARED TO 3.0T MRI FINDINGS IN THE LOCALISATION AND DIAGNOSIS OF PROSTATE CANCER: PRELIMINARY RESULTS OF A SINGLE CENTRE STUDY

Alexandre Pelzer, Julia Heinzelbecker, Matthias Kirchner, Stefan Schönberg, Philipp Sroebel, Dietmar Dinter, Maurice Stephan Michel

INTRODUCTION AND OBJECTIVES

Real-time sonoelastography (HI-RTE) can be used for prostate cancer (PCa) detection. We evaluated the role of HI-RTE by applying this method to patients undergoing radical retropubic prostatectomy (RRP) and comparing the results to 3.0 T MRI imaging and to whole mounted sections.

METHODS

Patients with biopsy proven PCa scheduled for RRP were included and underwent HI-RTE and 3.0 T MRI before surgery. HI-RTE was done by using a transrectal ultrasound probe (EUB-7500HV Hitachi medical systems with EUP-V53W probe). Three Tesla MRI (Siemens Magnetom Trio) was done with an endorectal coil as well as a body phased array coil using the following sequence protocol: multiplanar T2 w, diffusion weighted imaging (DWI), high resolution isotropic volume interpolated breathhold examination (VIBE), chemical shift imaging spectroscopy (CSI-MRS) and dynamic contrast enhanced T1 w (dce MRI) for evaluation of prostate perfusion. Areas suspicious for PCa were depicted and documented in a blinded fashion. RRP specimens were serially step sectioned and whole mounted, tumour areas were marked by felt pen and each prostate was divided into 16 sectors. Areas suspicious for PCa were correlated with the corresponding whole mounted sections by sector. HI-RTE images and MRI results compared to whole-mount sections were evaluated based on the reports on diagnostic findings out at the day of examination in blinded fashion. Evaluation was based on findings concerning the identification of the index tumor (A) and concerning PCa detection in each sector (B).

RESULTS

Until now 28 specimens with 448 prostate sectors were evaluated. Mean PSA was 7.5 ng/ml with Gleason Scores in between 6-8. Mean examination time was 9 (6 to 13 minutes) and 58 minutes for elastography and MRI examinations, respectively ($p < 0.005$). Sensitivity and specificity concerning identification of the index tumour (A) were 89.8% and 78.5% for elastography and 89.5% and 78.7% for MRI, respectively. Sensitivity and specificity concerning identification of PCa in each of the 448 sectors (B) were 60.5% and 78.3% for elastography and 45.6% and 84.8% for MRI, respectively.

CONCLUSIONS

HI-RTE is a sensitive imaging modality for the detection of PCa and proved to be a high-specific imaging modality for lesion characterization. In comparison to 3.0 T MRI including 5 protocols it has similar sensitivity and specificity. However, in contrast to other image modalities elastography seems to offer a less time consuming and more economic technique for PCa detection.

The Journal of Urology April 2010 (Vol. 183, Issue 4, Supplement, Page e832)

REAL-TIME BALLOON INFLATION ELASTOGRAPHY OF PROSTATE MIGHT SURPASS MRI FOR DETECTION OF PROSTATE CANCER

Masahiro Sumura, Yozo Mitsui, Naoko Arichi, Takeo Hiraoka, Koji Wake, Satoshi Honda, Hiroaki Yasumoto, Hiroaki Shiina, Mikio Igawa

INTRODUCTION AND OBJECTIVES

Although the efficacy of real-time tissue elastography (RTE) for prostate cancer detection has been reported, the procedure is highly operator dependent. We speculated that the use of a pressure device might decrease operator dependency and increase the detection rate of RTE. A pressure device driven water pressure was developed for this study, which we termed real-time balloon inflation elastography (RBIE), and the procedure investigated for its effectiveness in detecting prostate cancer.

METHODS

From July, 2008 to February, 2009, 87 patients had abnormal digital rectal examination (DRE), PSA, and/ or TRUS findings, and were enrolled in this study. Their median age was 73 years -old (range 54-89), median PSA was 7.6 ng/mL (range 0.8-2606.0), and the median number of biopsy cores obtained from each was 8 (range 8-10). All patients were examined with MRI prior to prostate needle biopsy and a total of 733 specimens obtained by systemic biopsies were studied. The findings of RTE, RBIE, TRUS, PDUS, and MRI [T2WI, dynamic contrast enhanced images imaging (DCEI)] were compared with histopathological findings of the biopsy specimens.

RESULTS

Prostate cancer was detected in 48 of 87 patients (55.2%), and 178 of 733 specimens (24.3%), of which 49, 56, and 73 specimens had Gleason scores of 5-6, 7, and 8-10, respectively. Clinical stage was T1c, T2a-c, T3a-b, and T4 in 6, 26, 10, and 6 cases, respectively. The sensitivity of RBIE, RTE, TRUS, PDUS, T2WI, and DCEI was 72.5%, 71.9%, 75.8%, 75.8%, 72.5%, and 71.3%, respectively, while specificity was 97.7%, 85.8%, 85.4% 86.6%, 89.7%, and 91.5%, respectively. Sensitivity and specificity of RBIE were both superior to those of MRI.

CONCLUSIONS

RBIE is known to be a low cost and less invasive procedure, while its prostate cancer detection capability may be superior to that of MRI, which is expensive and time consuming.

The Journal of Urology April 2010 (Vol. 183, Issue 4, Supplement, Page e780)

REAL-TIME TRUS ELASTOGRAPHY IN PROSTATE DISEASES

E. Panfilova, S. Alferov, A. Zubarev; Moscow/RU

Purpose: To evaluate the possibilities US Elastography in prostate pathology before biopsies.
Methods and Materials: 173 patients with suspected prostate pathology and a total PSA > 4ng/ml underwent TRUS and Elastography (EUB 900, Hitachi Medical, Japan) followed by biopsies. Prostate volume ranged 27-92cm³. Tissue elasticity of different hypoechoic foci and hyperechoic zones were compared with the final histopathology and biopsy specimens.
Results: Biopsy found out prostate cancer in 42 (24%) glands. The Gleason score ranged from 3 to 9 (mean 5). In 76,9% of cases the US Elastography findings correlated with the histological information. The prostate cancer on US Elastography visualized as a dark blue areas. The normal capsule is clearly visualized as a red rim. In 7 cases capsule cannot be visualized, and extracapsular disease was confirmed on histopathology. Hyperplastic nodules were seen as a green zones. Inflammatory changes were detected in all patients. In chronic inflammation fibrosis zones visualized as a light blue (68% of all cases). US Elastography showed sensitivity 95,7%, specificity 81,2%, accuracy 88,0%, PPV and NPV 92,7% and 82,5 respectively .
Conclusion: Elastography of the prostate is a sensitive new imaging for evaluation of the prostate tissue pathology.

European Congress of Radiology, 2010, March 5th – 9th, Vienna, Austria

IMAGING THE TESTIS USING REAL-TIME TISSUE ELASTOGRAPHY - SEEING WHAT YOU FEEL?: A PICTORIAL REVIEW.

Shah A, Rajayogeswaran B, Sellars ME, Sidhu PS, King's College Hospital, London

Real-time Tissue Elastography (RTE) has been clinically validated in the assessment of disease of the breast, thyroid and prostate. Exciting developments are being made in more widespread application of this technique.

Ultrasound is widely accepted as the mainstay of testicular imaging. Physical palpation of the testes is an important aspect of clinical evaluation. Incorporating the use of RTE in routine ultrasound provides additional objective information regarding tissue hardness, as well as shape and vascularity. This improves the diagnostic capability of ultrasound. In testicular imaging where ultrasound is often the only imaging modality used, this becomes particularly valuable.

Elastography is based on the principle that softer tissue deforms more under compression when compared to hard tissue that has been altered by disease processes. This 'tissue response' can be displayed as a colour map superimposed onto a conventional B mode image. The technique involves freehand compression which is easy to use, quick and reproducible. It can be performed at the time of B mode examination. Our images have been obtained using the Hitachi EUB-7500HV in RTE mode and using a linear array probe.

In this pictorial review, RTE appearances of testicular and paratesticular masses will be illustrated along with other common findings such as cysts, varicoceles and hydroceles.

Proceedings of the 21st Euroson Congress, 2009, Edinburgh, 6th – 8th December

IS REAL-TIME ELASTOGRAPHY TARGETED BIOPSY ABLE TO ENHANCE PROSTATE CANCER DETECTION? ANALYSIS OF DETECTION RATE BASED ON AN ELASTICITY SCORING SYSTEM.

Leo Pallwein, Fritz Aigner, Ralph Faschingbauer, Eva Pallwein, Germar Pinggera, Georg Bartsch, Georg Schaefer, Peter Struve, Florian Pedross, Werner Jaschke, Ferdinand Frauscher.
Medical University Innsbruck, Austria.

Objective: This prospective study was performed to evaluate real-time elastography (RTE) by using an elasticity score for targeted prostate biopsy compared with systematic biopsy in a PSA first line screening population.

Material and Methods: 383 patients were included with elevated PSA (mean: 7.0 ± 13.8) and scheduled for systematic biopsy. Prior to a 10 core systematic approach, a targeted biopsy with a limited number of cores (maximum 5) was performed. Targeted biopsy was based on findings in RTE. Stiff lesions were considered malignant. Appearance of elasticity of outer gland areas was divided into: Score 1: normal (regular stiffness), Score 2: indeterminate (inhomogeneously increased stiffness) and Score 3: suspicious (homogeneously increased stiffness). PCa detection rate of each elasticity score was compared with findings of the systematic biopsy.

Results: Sensitivity for PCa detection (134 of 383 patients; 35%) was 88.8% (119/134) for the RTE targeted biopsy and 76.9% (103/134) for the systematic biopsy.

Score 1: elasticity pattern was found in 143 patients, 17 of which (11.9%) showing cancer;

Score 2: elasticity was assessed in 140 patients, 37 of which (26.4%) showing cancer

and Score 3: elasticity appeared in 100 patients, 68 of which (68.0%) showing cancer.

The difference of detection rate between Score 1 to Score 3 groups was significant ($p < 0.001$). We found significant differences ($p < 0.001$) of Gleason scores, PSA values and prostate volumes between different elasticity score groups.

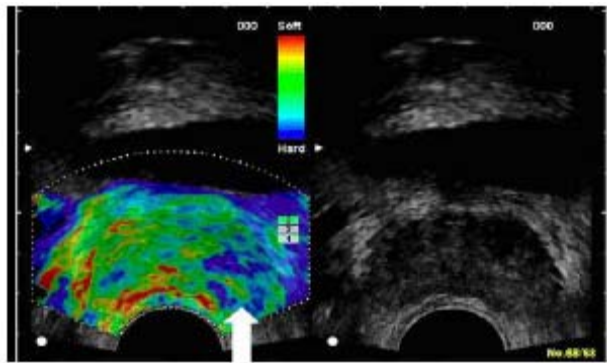


Figure 1: Typical appearance of a Score 2 elasticity pattern (arrow) fulfilling all criteria: inhomogeneous distribution of stiffness (i.e. alternating blue and green areas), diameter of each blue area of less than 5mm and reproducible after tilting the US probe.

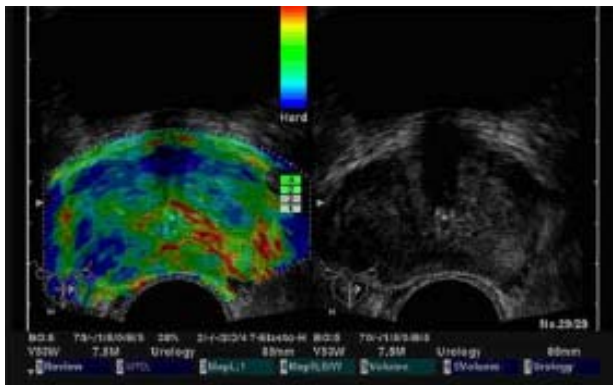


Figure 2: Typical appearance of a Score 3 elasticity pattern fulfilling all criteria: nearly homogeneous localized increase of stiffness (blue areas), diameter of at least 5mm and reproducible after tilting the US probe. Please notice the Score 2 stiffness pattern in the inner gland.

Conclusion: RTE by using the elasticity score improves PCa detection when compared with systematic biopsy.

References:

- [1] Krouskop TA, Wheeler TM, Kallel F, Garra BS, Hall T, Elastic moduli of breast and prostate tissues under compression, *Ultrason Imaging*, 20(4):260–74, Oct 1998.
- [2] Pallwein L, Mitterberger M, Struve P, Horninger W, Aigner F, Bartsch G, Gradl J, Schurich M, Pedross F, Frauscher F, Comparison of sonoelastography guided biopsy with systematic biopsy: impact on prostate cancer detection, *Eur Radiol.*, 17(9):2278–85, Sep 2007.
- [3] Frey H, Realtime elastography. A new ultrasound procedure for the reconstruction of tissue elasticity, *Radiologe*, 43: 850–855, 2003.
- [4] Shiina TD, Doyley MM, Bamber JC, Strain imaging using combined RF and envelope autocorrelation processing, *Proc of 1996 IEEE Ultrasonics Symp.*, 4:1331–1336, 1996.
- [5] Sumura M, Shigeno K, Hyuga T, Yoneda T, Shiina H, Igawa M, Initial evaluation of prostate cancer with real-time elastography based on step-section pathologic analysis after radical prostatectomy: A preliminary study, *Int J Urol.*, 14(9):811–6, Sep 2007.

Eighth International Conference on the Ultrasonic Measurement and Imaging of Tissue Elasticity, September 14 – 17, 2009, Vlissingen, The Netherlands

REAL-TIME ELASTOGRAPHY FOR PROSTATE CANCER DETECTION

Mss Ekaterina Panfilova, Mss Veronika Gazhonova, Mss Svetlana Churkina, Ms Elena Lukyanova, Mr Alexander Zubarev, Presidential Scientific Center, Russia

Objective: To evaluate the diagnostic possibilities of Real-time ultrasound (US) elastography imaging in diagnosis of prostate cancer in patients with elevated PSA level or with palpable prostate nodules.

Methods and Materials: 520 consecutive patients underwent TRUS (gray scale, color Doppler, elastography) with the EUB 900 (Hitachi Medical, Japan) using EUP-V53W of 6.5 MHz transducer (PSA level 4-14 ng/ml, prostate volume 40-95 cm³, mean age 63+/-9). Elastography (strain imaging) is capable to visualize displacements between ultrasonic image pairs of tissue under axial compression. Therefore differences in tissue architecture can be used to distinguish between normal

and cancer tissue. Sonoelasticity score of the suspicious for prostate cancer lesions were evaluated (from 1 to 4). Prostate sextant biopsies were performed in all cases. Sensitivity, specificity, accuracy, positive predictive value (PPV), negative predictive value (NPV) were calculated in all cases.

Results: 391 patients using sonoelastography were suspected to have prostate cancer. The sonoelastography was in agreement with histopathology results in 361 cases. Prostate cancer were characterized of 3.8+/-0.8 sonoelasticity score, compared to prostatitis - 1.7+/-0.9 ($p<0.001$), and BPH - 2.5+/-1.1 ($p<0.05$). Our study shows sensitivity - 97.4%, specificity - 75.4%, accuracy - 90.75%, PPV - 97.0%, NPV - 75.4%.

Conclusion: US elastography is a sensitive new imaging modality for the detection of prostate cancer. It offers additional information to improve conventional ultrasound methods.

12th World Congress of the World Federation for Ultrasound in Medicine and Biology, 30th August – 3rd September 2009, Sydney, Australia

PROSTATE CANCER DETECTION: BIOPSY FINDINGS BASED ON TISSUE ALTERATIONS IN REAL TIME ELASTOGRAPHY AND T2 WEIGHTED ENDORECTAL MAGNETIC RESONANCE IMAGING

Pallwein L. (1), Aigner F. (1), Horninger W. (2), Schocke M. (1), Frauscher F. (1)

(1) Dept. of Radiology, Innsbruck, Austria, (2) Dept. of Urology, Innsbruck, Austria

Introduction: This study was performed to compare prostate biopsy findings based on tissue alterations detected by real time elastography (RTE) and T2 weighted endorectal magnetic resonance imaging (T2w-eMRI) for detection of prostate cancer (PCa).

Material and Method: Retrospectively 34 patients (mean age: 62,9 years; range: 43-82 years) with elevated PSA levels (mean PSA: 9,2) were included. All patients underwent RTE (illustration of elasticity; EUB 8500, Hitachi) and eMRI (T2w imaging; Siemens, 1.5T) for assessment of tissue alterations. The matching of the findings of the 2 imaging modalities was performed by assigning tissue alterations to 6 outer gland areas. For targeted biopsy, suspicious areas were divided in 3 groups. Group A: tissue changes in both methods, Group B: changes in RTE alone, Group C: changes in T2w-eMRI alone. Additionally, all patients underwent a systematic 10 core biopsy ("gold standard").

Results: Overall, PCa was detected in 16 patients (gleason score: 5-8). RTE detected 27 suspicious areas, 19 of them were PCa positive, and T2w-eMRI detected 38 suspicious areas, 14 positive for PCa. We found 13 group A lesions (11 of them positive for cancer), 14 group B lesions (8 positive for cancer), and 25 group C lesions (3 of them positive for cancer).

Conclusions: Despite a small study population and a non-automated image fusion system between ultrasound and T2w-eMRI, this study showed, that the combination of findings in RTE combined with T2w-eMRI seems to be able to enhance visualization of PCa. Comparing the different modalities, RTE showed a higher sensitivity and specificity than T2w-eMRI for detection of PCa.

Focal Therapy and Imaging in Prostate and Kidney Cancer, June 10 – 13th, 2009, Amsterdam, The Netherlands

REAL-TIME ELASTOGRAPHY FOR THE DIAGNOSIS OF PROSTATE CANCER: EVALUATION OF ELASTOGRAPHIC MOVING IMAGES

Tomoaki Miyagawa¹, Masakazu Tsutsumi², Takeshi Matsumura³, Natsui Kawazoe², Satoru Ishikawa², Tatsuro Shimokama⁴, Naoto Miyanaga⁵ and Hideyuki Akaza⁵

¹Department of Urology, Kitaibaraki Municipal General Hospital, Ibaraki, ²Department of Urology, Hitachi General Hospital, Hitachi City, Ibaraki, ³Ultrasound Systems Division, Hitachi Medical Corporation, Kashiwa City, Chiba, ⁴Department of Pathology, Hitachi General Hospital and

⁵Department of Urology, Institute of Clinical Medicine, University of Tsukuba, Ibaraki, Japan

Objective: Elastography is a technique for detecting the stiffness of tissues. We applied

elastography for the diagnosis of prostate cancer and evaluated the usefulness of elastography for prostate biopsy.

Methods: The subjects of this study were 311 patients who underwent elastography during prostate needle biopsy at Hitachi General Hospital. Strain images obtained during compression of the prostate tissue were displayed on a monitor and recorded on the computer.

The elastographic moving images (EMI) were evaluated retrospectively. The evaluable images and biopsy results were compared in terms of the feasibility and accuracy.

Results: The median patient age was 67 years (range 50–85 years), the median serum level of prostate-specific antigen was 8.4 ng/ml (range 0.3–82.5 ng/ml) and the median prostate volume was 42.6 ml (range 12–150 ml). Among the 311 patients, prostate cancer was detected in 95 patients (30%) by biopsy. The diagnostic sensitivity was 37.9% for digital rectal examination (DRE) and 59.0% for transrectal ultrasonography (TRUS), whereas it was 72.6% for elastography and 89.5% for the combination of TRUS and elastography.

Elastography-positive EMIs with negative biopsies were eventually determined to be due to benign prostatic hyperplasia.

Conclusion: Elastography has a significantly higher sensitivity for the detection of prostate cancer than the conventionally used examinations including DRE and TRUS. It is a useful real-time diagnostic method because it is not invasive, and simultaneous evaluation is possible while performing TRUS.

Japanese Journal of Clinical Oncology (Advance Access published April 9, 2009)

REAL-TIME ELASTOGRAPHY IN THE DIAGNOSIS OF PROSTATE TUMOR

F.S. Ferrari ^{a,*}, A. Scorzelli ^a, A. Megliola ^a, F.M. Drudi ^c, S. Trovarelli ^b,
R. Ponchietti ^b

^a Department of Radiological Sciences, University of Siena, Siena, Italy

^b Section of Pediatrics, Obstetrics and Reproductive Medicine, Department of Urology, Siena, Italy

^c Department of Radiology, University of Rome “La Sapienza”, Rome, Italy

Aim: To assess the diagnostic gain of transrectal real-time elastography (RTE) compared to transrectal B-mode ultrasonography (US) in the detection of tumors in patients suspected of having prostate cancer.

Materials and methods: Eighty-four patients suspected of having prostate cancer on the basis of clinical and biochemical evaluation underwent transrectal US, RTE and transperineal prostate biopsy.

Results: Biopsy was considered the gold standard. Analysis related to the total number of patients showed a B-mode US sensitivity of 56%, specificity 80%, positive predictive value (PPV) 70% and negative predictive value (NPV) 67%. Analysis related to the total number of biopsy cores showed sensitivity 33%, specificity 92%, PPV 69% and NPV 73%. In the patient-related analysis, RTE sensitivity was 51%, specificity 75%, PPV 64% and NPV 64%, while the core-related analysis showed sensitivity 36%, specificity 93%, PPV 72% and NPV 74%. Comparison of B-mode US and RTE diagnostic accuracy in the detection of tumors located in the peripheral zone of the prostate gland showed a significant difference. Analysis related to the total number of biopsy cores harvested in the peripheral zone of the prostate gland showed a B-mode US sensitivity of 48%, specificity 81%, PPV 75% and NPV 58%, whereas RTE achieved the following values: sensitivity 66%, specificity 78%, PPV 77%, and NPV 67%.

Conclusions: RTE is a valid addition to B-mode US, and RTE reached a higher accuracy than B-mode US in the evaluation of the peripheral zone of the prostate gland and in the selection of appropriate biopsy sites.

Journal of Ultrasound (2009) 12, 22-31

REAL_TIME ELASTOGRAPHY (RTE) IN PATIENTS WITH PEYRONIE'S DISEASE: FIRST RESULTS OF A NEW IMAGING TECHNIQUE FOR THE DETECTION AND MEASUREMENT OF PLAQUES

S. Lahme

<http://www.eaustockholm2009.org/webcastplayer/?S=21832>

EAU Annual Congress, March 17 – 21st, 2009, Stockholm

IMPACT OF ELASTOGRAPHY IN CLINICAL DIAGNOSIS OF PROSTATE CANCER IN 351 PROSPECTIVELY RANDOMIZED PATIENTS

T. Eggert

<http://www.eaustockholm2009.org/webcastplayer/?S=21938>

EAU Annual Congress, March 17 – 21st, 2009, Stockholm

IS REAL-TIME ELASTOGRAPHY TARGETED BIOPSY ABLE TO ENHANCE PROSTATE CANCER DETECTION? AN ANALYSIS OF DETECTION RATE USING AN ELASTICITY-SCORING SYSTEM

L. Pallwein, F. Aigner, V. Spiss, M. Mitterberger, W. Jaschke, F. Frauscher; *Innsbruck/AT*

Purpose: Real-time elastography (RTE) has already shown its ability to detect PCa. This prospective study was performed to evaluate RTE for targeted prostate biopsy in a PSA screening population in comparison to cancer detection rate of systematic biopsy.

Methods and Materials: Included were 383 patients with elevated PSA (mean: 7.0 ± 13.8) and scheduled for systematic biopsy. Before systematic approach, a targeted biopsy with a limited number of cores (maximum 5) was performed. Targeted biopsy was based on findings in RTE. Stiff lesions were considered malignant. Appearance of elasticity of outer gland areas was divided into: score 1-normal (regular stiffness), score 2- indeterminate (inhomogeneously increased stiffness), and score 3-suspicious (homogeneously increased stiffness). PCa detection rates of each stiffness grades were compared with findings of systematic biopsy.

Results: Sensitivity for PCa detection (134 of 383 patients; 35%) was 91.0% (122/134) for RTE targeted biopsy and 76.9% (103/134) for systematic biopsy. Score 1 elasticity pattern was found in 129 patients, 3 of them (2.3%) showed cancer, score 2 elasticity pattern in 146 patients, 42 of them (28.8%) showed cancer, and score 3 elasticity pattern in 108 patients, 89 of them (82.4%) showed cancer. The correlation between stiffness grade and Gleason Score was significant. The prostate volume and the PSA also were correlated with the stiffness grades.

Conclusion: RTE has already shown its value for PCa detection. The use of a stiffness grading system seems to be able to further enhance the PCa detection rate and can increase the diagnostic accuracy of RTE.

European Congress of Radiology, March 6 – 9th, 2009, Vienna, Austria

REAL-TIME SONOELASTOGRAPHY IN PEYRONIE`S DISEASE: PRELIMINARY RESULTS IN DIAGNOSIS AND STAGING

V. Gazhonova, L. Ivanchenko, A. Zubarev; *Moscow/RU*

Purpose: To assess the value of sonoelastography in Peyronie`s disease (PD).

Methods and Materials: In 22 patients (pts) with clinical presentation of PD, a routine US examination (B-mode and power Doppler) after an intracavernous injection of prostaglandin E1 was performed. An additional qualitative measurement of tissue elasticity using sonoelastography was performed by another radiologist. The plaques themselves, surrounding plaque tissue and regions of thickening of tunica albuginea (TA) were evaluated for stiffness (blue indicated hard zone and red indicated soft zone). The size of the plaques and the size of the stiffened region around them were measured. The real-time elastography findings were compared with conventional US and with CE-MRI data.

Results: In 22 pts, 42 plaques were found. Ten pts had acute stage (18 plaques) confirmed by CE-MRI and 12 pts had chronic stage (24 plaques). Conventional US was able to detect 15 pts with acute stage and sonoelastography enabled the detection of 3 more. Inflammatory changes in the TA showed increase in tissue stiffness and the size of the stiffened region around the plaques were larger in pts with acute stage ($P < 0.05$) than in those with chronic stage. Elastography was able to differentiate between inflammatory and non-inflammatory changes in the thickened TA regions.

Conclusion: Our preliminary findings showed that sonoelastography improved the detection of acute stage PD and provided additional information on inflammatory changes in the surrounding plaques tissue. The information obtained by real-time elasticity imaging method can be detected and represented more rapidly and with higher accuracy than with conventional methods.

European Congress of Radiology, March 6 – 9th, 2009, Vienna, Austria

PROSTATE ULTRASOUND ELASTOGRAPHY IN CANCER DETECTION

E. Panfilova, A. Emelyanenko, S. Alferov, A. Zubarev; *Moscow/RU*

Purpose: To evaluate the diagnostic possibilities of ultrasound (US) elastography imaging in diagnosis of prostate cancer in patients with elevated PSA level or with palpable prostate nodules.

Methods and Materials: 400 consecutive patients underwent TRUS (gray scale, color Doppler, elastography) with the EUB 900 (Hitachi Medical, Japan) using EUP-V53W of 6.5 MHz transducer (PSA level 4-14 ng/ml, prostate volume 40-95 cm³, mean age 63+/-9). Sonoelasticity score of the suspicious for prostate cancer lesions were evaluated (from 1 to 4). Prostate sextant biopsies were performed in all cases. Sensitivity, specificity, accuracy, positive predictive value (PPV), negative predictive value (NPV) were calculated in all cases.

Results: 301 patients using sonoelastography were suspected to have prostate cancer. The sonoelastography was in agreement with histopathology results in 278 cases. Prostate cancer were characterized by 3.8+/-0.8 sonoelasticity score, compared to prostatitis - 1.7+/-0.9 ($p < 0.001$), and BPH - 2.5+/-1.1 ($p < 0.05$). Our study shows sensitivity - 97.4%, specificity - 75.4%, accuracy - 90.75%, PPV - 97.0%, NPV - 75.4%.

Conclusion: US elastography shows high potential in prostate cancer diagnostics. It offers additional information that increased the sensitivity of conventional ultrasound methods.

European Congress of Radiology, March 6 – 9th, 2009, Vienna, Austria

THE UTILITY OF TRANSRECTAL REAL-TIME ELASTOGRAPHY IN THE DIAGNOSIS OF PROSTATE CANCER

Kamoi K., Okihara K., Ochiai A., Ukimura O., Mizutani Y., Kawauchi A., Miki T
Department of Urology, Kyoto Prefectural University of Medicine, Kyoto, Japan

The aim of this study is to evaluate the diagnostic performance of transrectal real-time elastography (TRTE) to differentiate benign from malignant prostatic lesions, with pathologic diagnosis obtained by prostatic needle biopsy. Conventional gray scale transrectal ultrasonography (TRUS) and power Doppler ultrasonography (PDUS) were performed in 107 men who had elevated serum prostate-specific antigen level >4 ng/mL or abnormal findings on digital rectal examination. For baseline TRUS and PDUS imaging, the suspicion of carcinoma was scored using previously proposed five-point subjective scale. For TRTE imaging, we used newly adopted five-point subjective scale based on the degree and distribution of strain in relation to hypoechoic area, which simultaneously displayed on B-mode image. All patients underwent transperineal systematic 8-cores biopsies, as well as up to four cores of targeted biopsy from suspicious area by TRUS, PDUS and/or TRTE. The samples were diagnosed pathologically and compared with the findings of TRUS, PDUS and TRTE. Prostate cancer was detected in 40 (37%) of 107 patients. When a cutoff point of 3 (displaying focal asymmetric lesion without strain not related to hypoechoic lesion) was used, TRTE had 68% sensitivity, 81 % specificity and 76% accuracy. TRTE was comparable with PDUS (70% sensitivity, 75% specificity and 73% accuracy) and had significantly higher sensitivity than TRUS (68% vs. 50%, $p = 0.027$). Combination of TRTE with PDUS increased sensitivity to 78%. The detection rate of directed biopsy from suspicious area in either TRTE or PDUS (TRTE+PDUS-directed biopsy) was 29% (31/107) by patient and was comparable with systematic biopsy (31 %, 33/107, $p = 0.86$), whereas the detection rate of TRTE+PDUS-directed biopsy by core (55/111, 50%) was significantly higher than systematic biopsy (132/856, 15%, $p < 0.0001$). For assessing prostatic lesions, TRTE with B-mode image-based scoring had almost the same diagnostic performance as PDUS. Although TRTE+ PDUS-directed biopsy detected comparable number of cancers with systematic biopsy, both techniques should be used supplementarily for minimizing the number of missing cancers.

Ultrasound in Med. and Biol. 2008; 34(7):1025-1032

IS REAL-TIME ELASTOGRAPHY TARGETED BIOPSY ABLE TO ENHANCE PROSTATE CANCER DETECTION? VALUE OF AN ELASTICITY-SCORING SYSTEM

Leo Pallwein, Friedrich Aigner, Germar Pinggera, Michael Mitterberger, Ferdinand Frauscher, Georg Bartsch, Innsbruck, Austria

INTRODUCTION AND OBJECTIVE: Real-time elastography (RTE) has already shown its ability to detect Pca. This prospective study was performed to evaluate RTE for targeted prostate biopsy in a PSA first line screening population in comparison to cancer detection rate of systematic biopsy.

METHODS: Included were 383 patients with elevated PSA (mean: 7.0 ± 13.8) and scheduled for systematic biopsy. Before systematic approach a targeted biopsy with a limited number of cores (maximum 5) was performed. Targeted biopsy was based on findings in RTE. Stiff lesions were considered malignant. Appearance of elasticity of outer gland areas was divided into: score 1- normal (regular stiffness), score 2- indeterminate (inhomogeneously increased stiffness), and score 3- suspicious (homogeneously increased stiffness). PCa detection rate of elasticity score were compared with findings of systematic biopsy.

RESULTS: Sensitivity for PCa detection (134 of 383 patients; 35%) was 91.0% (122/134) for RTE targeted biopsy and 76.9% (103/134) for systematic biopsy. Score 1 elasticity pattern was found in 129 patients, 3 of them (2.3%) showed cancer, Score 2 elasticity pattern in 146 patients, 42 of them (28.8%) showed cancer, and Score 3 elasticity pattern in 108 patients, 89 of them (82.4%) showed cancer. The correlation between elasticity score and Gleason Score was weak. The prostate volume and the PSA also were weak correlated with the stiffness grades.

CONCLUSIONS: RTE has already shown its value for PCa detection. The use of the elasticity score seems to be able to further enhance the PCa detection rate and can increase the diagnostic accuracy of RTE.

EVALUATION OF PROSTATE CANCER DETECTION WITH ULTRASOUND REAL-TIME ELASTOGRAPHY: A COMPARISON WITH STEP SECTION PATHOLOGICAL ANALYSIS AFTER RADICAL PROSTATECTOMY.

Salomon G, Köllerman J, Thederan I, Chun FK, Budäus L, Schlomm T, Isbarn H, Heinzer H, Huland H, Graefen M.

Department of Urology, University Hospital Hamburg-Eppendorf, Hamburg, Germany; Martini Clinic, Prostate Cancer Center, Hamburg, Germany.

BACKGROUND: Conventional gray scale ultrasound has a low sensitivity and specificity for prostate cancer detection. Better imaging modalities are needed.

OBJECTIVE: To determine sensitivity and specificity for prostate cancer detection with ultrasound-based real-time elastography (elastography) in patients scheduled for radical prostatectomy (RP).

DESIGN, SETTING, AND PARTICIPANTS: Between July and October 2007, 109 patients with biopsy-proven localized prostate cancer (PCa) underwent elastography before RP. The investigator was blinded to clinical data.

MEASUREMENTS: A EUB-6500HV ultrasound system with a V53W 7.5MHz end-fire transrectal probe was used preoperatively. Areas found to be suspicious for PCa were recorded for left and right side of the apex, mid-gland, and base. These findings were correlated with the obtained whole-mount sections after RP.

RESULTS AND LIMITATIONS: Sensitivity and specificity for detecting PCa were 75.4% and 76.6%, respectively. A total of 439 suspicious areas in elastography were recorded, and 451 cancerous areas were found in the RP specimens. Positive predictive value, negative predictive value, and accuracy for elastography were 87.8%, 59%, and 76%, respectively. Nevertheless, there are limitations to our studies because we investigated specific patients scheduled for RP with apparent PCa. Whether elastography is practical as a diagnostic tool or can be used to target a biopsy and be at least as sensitive in tumor detection as extended biopsy schemes has yet to be determined.

CONCLUSION: Elastography can detect prostate cancer foci within the prostate with good accuracy and has potential to increase ultrasound-based PCa detection. Further studies need to be done to approve these data and to evaluate whether tumor detection can be increased by elastography-guided biopsies.

Eur Urol. 2008 Dec;54(6):1354-62

IS REAL-TIME ELASTOGRAPHY TARGETED BIOPSY ABLE TO ENHANCE PROSTATE CANCER DETECTION? AN ANALYSIS OF DETECTION RATE USING AN ELASTICITY-SCORING SYSTEM

Pallwein P.L.¹, Aigner E.¹, Frauscher F.¹, Hominger W.², Pelzer A.², Bartsch G.²

¹Medical University, Dept. of Radiology, Innsbruck, Austria, ²Medical University, Dept. of Urology, Innsbruck, Austria

INTRODUCTION & OBJECTIVES: Real-time elastography (RTE) has already shown its ability to detect PCa. This prospective study was performed to evaluate RTE for targeted prostate biopsy in a PSA first line screening population in comparison to cancer detection rate of systematic biopsy.

MATERIAL & METHODS: Included were 383 patients with elevated PSA (mean: 7.0± 13.8) and scheduled for systematic biopsy. Before systematic approach a targeted biopsy with a limited number

of cores (maximum 5) was performed. Targeted biopsy was based on findings in RTE. Stiff lesions were considered malignant. Appearance of elasticity of outer gland areas was divided into: score 1-normal (regular stiffness), score 2 indeterminate (inhomogeneously increased stiffness), and score 3-suspicious (homogeneously increased stiffness). PCa detection rate of each stiffness grades were compared with findings of systematic biopsy.

RESULTS: Sensitivity for PCa detection (134 of 383 patients; 350/0) was 91.0% (122/134) for RTE targeted biopsy and 76.9% (103/134) for systematic biopsy. Score 1 elasticity pattern was found in 129 patients, 3 of them (2.3%) showed cancer, Score 2 elasticity pattern in 146 patients, 42 of them (28.8%) showed cancer, and Score 3 elasticity pattern in 108 patients, 89 of them (82.40%) showed cancer. The correlation between stiffness grade and Gleason Score was significant. The prostate volume and the PSA also were correlated with the stiffness grades.

CONCLUSIONS: RTE has already shown its value for PCa detection. The use of a stiffness grading systems seems to be able to further enhance the PCa detection rate and can increase the diagnostic accuracy of RTE.

23rd Annual European Association of Urology Congress, March 26 – 29th, 2008, Milan, Italy

EVALUATION OF PROSTATE CANCER DETECTION WITH REAL-TIME ELASTOGRAPHY: A COMPARISON WITH STEP SECTION PATHOLOGICAL ANALYSIS AFTER RADICAL PROSTATECTOMY

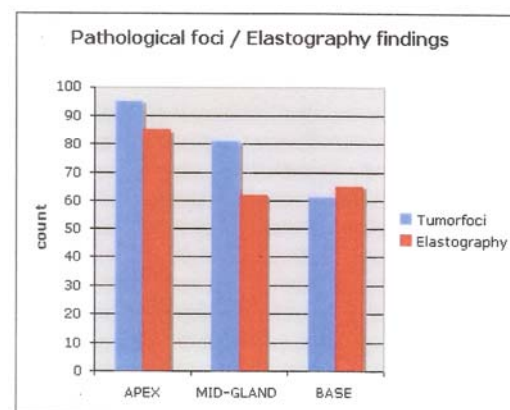
Salomon G.¹, Kollermann J.², Thederan I.¹, Schlomm T.¹, Budaus L.H.¹, Isbarn H.I.¹, Heinzer H.¹, Huland H.³, Graefen M.¹

¹University Medical Center Hamburg-Eppendorf, Martini Clinic, Prostate Cancer Center, Hamburg, Germany, ²University Medical Center Hamburg-Eppendorf, Department of Pathology, Hamburg, Germany, ³University Medical Center Hamburg-Eppendorf, Department of Urology and Martini Clinic, Prostate Cancer Center, Hamburg, Germany

INTRODUCTION & OBJECTIVES: Promising results for prostate cancer detection (PCA) using ultrasound based real-time-elastography (elastography) have been previously reported on a small number of patients. To determine the impact of elastography on a large cohort of patients scheduled for radical prostatectomy (RP).

MATERIAL & METHODS: Overall 67 patients with biopsy proven PCA underwent elastography before radical prostatectomy. Mean PSA was: 6,78ng/ml. The investigator was blinded to all clinical data. An EUB-6500HV ultrasound system (Hitachi Medical, Japan) with a 7.5 bi-plane transrectal endfire probe was used. Areas found to be suspicious for PCA were recorded for apex, mid-gland and base. These findings were correlated to all cancerous areas obtained from whole mountain sections after RP.

RESULTS: Elastography resulted in a sensitivity of 75.9 % to 89.1% and sensitivity of 67.9 % to 77.8% depending on the location. (table 1, fig 1) In total 212 (1 to 7) suspicious areas or foci were documented for elastography compared to 237 (1 to 6) tumour foci found in the histopathological evaluation. Tumour foci distribution (figure 1) in the prostatectomy specimen was 400/0 in the apex, 31 % in the mid-gland, and the base region (250/0) without any significant differences for both sides of the gland. Best elastography results were obtained in the apex.



Location	Sensitivity	Specificity
Apex	89.1%	68.4%
Mid-Gland	83.8%	67.9%
Base	75.9%	77.8%

CONCLUSIONS: Elastography has high potential to improve PCA detection within the prostate. If it can be used for targeted biopsies and elastography is as sensitive in tumour detection as extended biopsy schemes has to be determined.

23rd Annual European Association of Urology Congress, March 26 – 29th, 2008, Milan, Italy

PROSTATE CANCER DIAGNOSIS: VALUE OF REAL-TIME ELASTOGRAPHY.

Pallwein L, Aigner F, Faschingbauer R, Pallwein E, Pinggera G, Bartsch G, Schaefer G, Struve P, Frauscher F.

Department of Radiology, Medical University Innsbruck, Innsbruck, Austria, leo.pallwein@uibk.ac.at.

It is well known that prostate cancer (PCa) has a higher cell density than the surrounding normal tissue. This increased cell density leads to an alteration in tissue elasticity, which can be measured and displayed by sonographic-based elastography under real-time conditions. Real-time sonoelastography (RTE) has been proven capable to visualize PCa areas as "hard" lesions and therefore can be used for PCa detection and for targeted ultrasound-guided biopsy. Further applications such as the assessment of local extent of PCa should be considered. This overview describes the capabilities, advantages, and limitations of this new ultrasound technique for PCa diagnosis.

Abdom Imaging. 2008 Nov-Dec;33(6):729-35. Review

ULTRASOUND OF PROSTATE CANCER: RECENT ADVANCES.

Pallwein L, Mitterberger M, Pelzer A, Bartsch G, Strasser H, Pinggera GM, Aigner F, Gradl J, Zur Nedden D, Frauscher F.

Department of Radiology II, Medical University of Innsbruck, Anichstrasse 35, 6020, Innsbruck, Austria, Leo.Pallwein@uibk.ac.at.

Prostate cancer is the most common cancer in men. In the future, a significant further increase in the incidence of prostate cancer is expected. Therefore, improvement of prostate cancer diagnosis is a main topic of diagnostic imaging. The systematic prostate biopsy ("ten-core biopsy") is now the "gold standard" of prostate cancer diagnosis but may miss prostate cancer. Contrast-enhanced colour Doppler ultrasound (US) and elastography are evolving methods that may dramatically change the role of US for prostate cancer diagnosis. Contrast-enhanced colour Doppler US allows for investigations of the prostate blood flow and consequently for prostate cancer visualization and therefore for targeted biopsies. Comparisons between systematic and contrast-enhanced targeted biopsies have shown that the targeted approach detects more cancers and cancers with higher Gleason scores with a reduced number of biopsy cores. Furthermore, elastography, a new US technique for the assessment of tissue elasticity has been demonstrated to be useful for the detection of prostate cancer, and may further improve prostate cancer staging. Therefore, contrast-enhanced colour Doppler US and elastography may have the potential to improve prostate cancer detection, grading and staging. However, further clinical trials will be needed to determine the promise of these new US advances

European Radiology 2008 Apr;18(4):707-15

TISSUE COMPRESSION BY BALLOON INFLATION METHOD IMPROVES THE QUALITY OF ELASTOGRAPHY FOR PROSTATE CANCER DETECTION

Dr Tsutsumi, Hitachi General Hospital

Purpose: The problem of elastography of the prostate with free-hand compression is its examiner dependency. Appropriate compression maintaining the same plane by transrectal manipulation is too difficult to obtain correct elastographic moving images (EMI), and EMIs are sometimes less reproducible. In order to overcome these problems, we have tried a balloon inflation method (real-time balloon inflation elastography: RBIE). We evaluated the feasibility and efficacy of RBIE using prostatectomy specimens.

Method and materials: Thirty-nine prostatectomy specimens were compared using transverse pathology sections by each EMI. EMIs were obtained by repetition of balloon inflation and deflation at the time of prostate biopsy. Mean patient age was 66 years (range 57 to 78), and mean PSA was 10.7 ng/mL (range 4.1 to 29 ng/mL).

Results: The balloon inflation method easily maintained the same plane, and repeatable and examiner-independent images were consequently obtained. The quality of EMI was much better than with free-hand compression, and it depended on the initial inflation volume. The overall detection rate was 79%: 5 cases (13%) showed complete agreement of all EMIs with tumor location, 26 cases (66%) agreed with tumor location, but showed partial disagreement, and 8 cases (21%) showed disagreement with elastographic findings of tumor location or were undetectable by elastography. Dividing the prostate into three different regions (anterior, middle, posterior), 24/33 (73%) anterior tumors, 15/21 (71%) middle tumors and 12/32 (55%) posterior tumors were detected by RBIE.

Conclusion: RBIE was able to overcome the problems of elastography with free-hand compression, and showed high detection rate of the tumor, especially in unpalpable regions. Thus, RBIE is feasible, and will be a promising tool in conjunction with B mode for prostate cancer detection; however, new problems with the balloon method exist: Multiple reflections generated at the balloon membrane and air bubbles in the balloon obstruct ultrasound travel. These are issues to be overcome in our future studies.

Clinical relevance/application: Tissue compression by balloon inflation system improves the quality of elastography, and this technique is promising for prostate cancer detection.

Radiological Society of North America 93rd Scientific Assembly and Annual Meeting November 25th – 30th, 2007, Chicago, USA

PROSTATE CANCER AND EXTRACAPSULAR EXTENSION (ECE): ASSESSMENT BY SONOELASTOGRAPHY IN COMPARISON WITH MRI – A PRELIMINARY STUDY.

L. Pallwein, F.H. Aigner, E. Pallwein, D. zurNedden, F. Frauscher.

Medical University Innsbruck, Department of Radiology 2, Innsbruck, AUSTRIA.

Background: SonoElastography (SE) has already shown its ability to detect prostate cancer areas based on increased tissue stiffness. Furthermore, this method is able to delineate the integrity of the prostate capsule as a soft rim artifact surrounding the outer border of the organ.

Aims: The goal of this study was the comparison of SE to structural MRI for assessment of the organ exceeding growth (ECE) of prostate cancer.

Methods: 15 patients with clearly elevated PSA (> 10, mean PSA 21± 9) and suspicious digital rectal examination findings were included in this study. Pretreatment staging was performed with SonoElastography (EUB-8500, Hitachi Ultrasound, Japan) for cancer detection and delineation of the prostate capsule, based on the fact that tumor tissue is displayed as a stiff area (colored in blue) and a regular bordered prostate is surrounded by a "soft rim artifact" (colored in red). At the site of ECE, this sign is interrupted (arrows in Figure 1 c and d). The results of SonoElastography were compared with T2 and contrast enhanced T1 weighted MRI images using an endorectal coil (Siemens Symphony, 1.5 T). Both imaging methods were compared to the histopathologic findings after radical prostatectomy.

Results: The histopathologic findings after radical prostatectomy showed an infiltration of the prostate capsule and a cancer extending into the periprostatic fat tissue (9 cases) or into the seminal vesicles (5 cases) in 11 of 15 patients. All of these tumors were staged T3b and T4. Cancers could be well detected with SonoElastography in all patients. SonoElastography showed an interruption of the soft rim sign in 8 patients and an increased stiffness of seminal vesicles in 4 cases. MRI was also able to

delineate cancer areas in all cases and showed a bulging of the capsule and other signs of infiltration of the periprostatic fat tissue clearly in 7 cases (arrows in Figure 1 a and b). An infiltration of the seminal vesicles could be detected with MRI in 5 cases.

Conclusion: On the one hand, SonoElastography detected all cancer areas. On the other hand, this method was able to delineate the prostate capsule and showed remarkable strength in the prediction of ECE. These results correlated well with MRI and histopathologic findings.

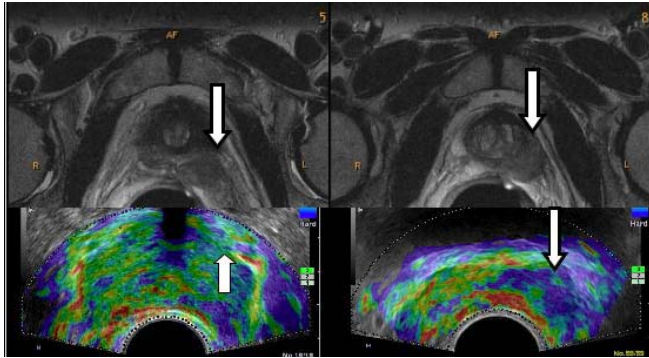


Figure 1: (a) and (b) MRI Images, (c) and (d) SonoElastography Images

Sixth International Conference on the Ultrasonic Measurement and Imaging of Tissue Elasticity, November 2nd – 5th, 2007, Santa Fe, New Mexico, USA

EARLY PROSTATE CANCER DETECTION: FINDINGS OF SONOELASTOGRAPHY IN COMPARISON TO ENDORECTAL MRI.

L. Pallwein, F.H. Aigner, E. Pallwein, D. zurNedden1, F. Frauscher.

Medical University Innsbruck, Department of Radiology 2, Innsbruck, AUSTRIA

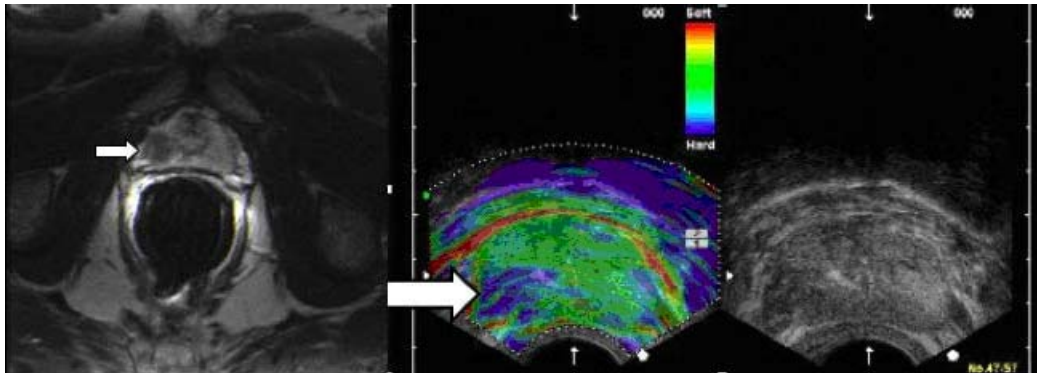
Aims: To assess the value of SonoElastography for detection of early prostate cancer in comparison to endorectal MRI.

Material and Methods: Fifty patients with elevated PSA blood values (ranging from 1.5 to 6.0) were examined with endorectal SonoElastography (Examiner 1; Hitachi, Japan), during which the elasticity of prostate tissue was displayed from red (soft) to blue (hard). Hard lesions were considered as malignant. The findings of SonoElastography were compared with T2w and contrast enhanced T1w endorectal MRI images (Examiner 2; Siemens, 1.5T). Suspicious areas were divided in 3 groups. Group A: tissue changes in both methods, (see figure) Group B: changes in SonoElastography alone, Group C: changes in MRI alone. All these areas were selected for US guided targeted prostate biopsy with 2 cores from each lesion. Subsequently systematic biopsy was performed.

Results: Overall 87 areas (174 cores) were selected in Group A, 24 in Group B (48 cores), and 14 in Group C (28 cores) for targeted biopsy. Targeted biopsy detected cancer in 18/50 patients (Gleason 5–7), whereas the systematic biopsy detected cancer in 14 patients. In Group A 32 cores (18%) were positive for cancer, in Group B 6 cores (13%), in Group C 4 cores (12%) and in the systematic biopsy 31/500 cores (6%).

Conclusion: With the limitation of a small study population SonoElastography combined with MRI seems to be able to enhance visualization of early prostate cancer.

Figure 1:



Sixth International Conference on the Ultrasonic Measurement and Imaging of Tissue Elasticity, November 2nd – 5th, 2007, Santa Fe, New Mexico, USA

INITIAL EVALUATION OF PROSTATE CANCER WITH REAL-TIME ELASTOGRAPHY BASED ON STEP-SECTION PATHOLOGIC ANALYSIS AFTER RADICAL PROSTATECTOMY: A PRELIMINARY STUDY.

Sumura M, Shigeno K, Hyuga T, Yoneda T, Shiina H, Igawa M.

Department of Urology, Shimane University School of Medicine, Shimane, Japan.

Objective: To determine whether real-time elastography can be used to detect prostate cancer as a relatively non-invasive modality based on the tissue strain value.

Patients and Methods: Seventeen patients underwent real-time elastography in conjunction with digital rectal examination (DRE), conventional gray-scale transrectal ultrasonography (TRUS), color Doppler ultrasonography (CDUS), and magnetic resonance imaging (MRI) prior to radical prostatectomy. The elastogram was compared to findings of conventional modalities and pathological findings of prostatectomy specimens. To obtain the elastogram, compression of the prostate was performed along with a visual indicator on a video screen.

Results: Twenty of 27 pathologically confirmed tumors were detected with real-time elastography. The cancer detection rate with real-time elastography was superior to the rates of other modalities and nearly equal to both on the anterior side (75.0%) and the posterior side (73.7%) of the prostate. A higher tumor detection rate for real-time elastography was observed for tumors with a higher Gleason score and larger tumor volume.

Conclusion: In our preliminary study, real-time elastography in conjunction with gray-scale TRUS is a non-invasive modality to detect prostate cancer.

Int J Urol. 2007 Sep;14(9):811-6.

THE IMPACT OF REAL-TIME TISSUE ELASTICITY IMAGING (ELASTOGRAPHY) ON THE DETECTION OF PROSTATE CANCER: CLINICOPATHOLOGICAL ANALYSIS.

Tsutsumi M, Miyagawa T, Matsumura T, Kawazoe N, Ishikawa S, Shimokama T, Shiina T, Miyanaga N, Akaza H.

Department of Urology, Hitachi General Hospital, Johnan-cho 2-1-1, Hitachi, Ibaraki, 317-0077, Japan, masakazu.tsutsumi.zy@hitachi.com.

BACKGROUND: We evaluated the accuracy and feasibility of real-time elastography for detecting prostate cancer, using prostatectomy specimens.

METHODS: This study was based on clinicopathological findings in 51 patients with prostate cancer who were referred for elastography at the time of prostate biopsy. We compared transverse pathology sections with elastographic moving images (EMIs) to determine the detection rate of cancer, the relationship between tumor location and the elastographic findings, and the relationship between the Gleason score and the elastographic findings.

RESULTS: In 15 patients (29%), all EMIs were in complete agreement with tumor location (category I), in 28 patients (55%), the EMIs agreed with tumor location, but showed some disagreement (category II), and in 8 patients (16%) there was disagreement of the elastographic findings with tumor location or the tumors were undetectable by elastography (category III). However, in category III, all tumors were detected as low-echoic by B-mode ultrasonography. We divided the prostate into three different regions (anterior, middle, and posterior), and found that 30/32 (94%) anterior tumors, 13/17 (76%) middle tumors, and 16/28 (57%) posterior tumors were detected by elastography. The proportions of cancers detected by elastography (categories I+II/total) was 100% in the patients with a Gleason score of 6, 85% in those with a score of 7 or 8, and 63% in those with a score of 9 or 10.

CONCLUSION: Real-time elastography in conjunction with B-mode ultrasonography significantly improves the detection of prostate cancer. One of the characteristic findings of elastography is its excellent detection of anterior tumors. The low detection rate of high-grade tumors in this analysis was likely due to the predominance of high-grade tumors in a peripheral location compared to the anterior location of the low-grade tumors.

Int J Clin Oncol. 2007 Aug;12(4):250-5. Epub 2007 Aug 20.

REAL-TIME ELASTOGRAPHY FOR DETECTING PROSTATE CANCER: PRELIMINARY EXPERIENCE.

Pallwein L, Mitterberger M, Struve P, Pinggera G, Horninger W, Bartsch G, Aigner F, Lorenz A, Pedross F, Frauscher F.

Department of Radiology II, Medical University Innsbruck, Austria.

OBJECTIVE To assess the use of real-time elastography (RTE) for detecting prostate cancer in patients scheduled for radical prostatectomy (RP), as most solid tumours differ in their consistency from the deriving tissue, and RTE might offer a new tool for cancer detection.

PATIENTS AND METHODS We examined 15 patients (mean age 56 years, sd 6.2, range 46-71) with RTE, using an ultrasonography (US) system with a 7.5-MHz transrectal probe as a transducer. RTE is capable of visualizing displacements between pairs of US images of tissues when placed under axial compression. The stiffness of the lesion was displayed from blue (soft) to black (hard). Hard lesions with a diameter of ≥ 5 mm were considered as malignant. All patients had the diagnosis of prostate cancer confirmed by biopsy and had a mean (range) prostate specific antigen (PSA) level of 4.6 (1.4-16.1) ng/mL; all were scheduled for RP. US was performed by two investigators and interpreted by consensus. Cancer location and size was determined in the RTE mode only. One pathologist classified tumour location, grade and stage. The RTE findings were compared with the pathological findings.

RESULTS There were no major complications during RP in any patient; all had a pT2 tumour on histopathological examination, the Gleason score was 5-9 and the mean (range) tumour size 1.1 (0.6-2.5) cm. Thirty-five foci of prostate cancer were present at the pathological evaluation; multiple foci were found in 11 of the 15 glands. RTE detected 28 of 35 cancer foci (sensitivity 80%). The per-patient analysis showed that RTE detected at least one cancer area in each of the 15 patients. Only

four sites with false-positive findings on RTE and no histopathological correlation were detected; these findings were obtained in the first five patients (period of learning).

CONCLUSIONS RTE can be used to visualize differences in tissue elasticity. Our results show that RTE allows the detection of prostate cancer and estimation of tumour location and size. RTE of the prostate is a new imaging method with great potential for detecting prostate cancer.

BJU Int. 2007 Jul;100(1):42-6

REAL-TIME ELASTOGRAPHY ACCURATELY DETECTS PROSTATE CANCER

By: Reuters Health 7/30/2007

NEW YORK (Reuters Health), Jul 30 - Real-time elastography accurately detects prostate cancer in men scheduled for radical prostatectomy, according to a report in the July *BJU International*.

"Elastography is a contrast-media-free technique, which allows for detection of suspicious areas in the outer gland," Dr. Leo Pallwein from Medical University Innsbruck, Austria, told Reuters Health. "It has the potential to become a reliable screening tool in men with elevated PSA."

Dr. Pallwein and colleagues assessed the value of elastography for detecting prostate cancer in 15 men scheduled for radical prostatectomy. Elastography detected 28 of 35 cancer foci (80% sensitivity), the authors report, but missed seven foci, most of them in the inner gland or in the basal area of the outer gland. The only four sites with false-positive findings were obtained in the first five patients, the investigators say, "while gaining experience with the technique."

There was no correlation between PSA levels, Gleason scores, and elastography results.

"Elastography needs some weeks to overcome the learning curve, but this technique can be helpful in detecting cancer without use of contrast agent," Dr. Pallwein said.

"Elastography is successfully used for cancer detection in the prostate, thyroid gland, breast, and pancreas," Dr. Pallwein explained. "Further technical developments can improve and establish this technique in the daily routine examination."

BJU International 2007;100:42-46.

VALUE OF CONTRAST-ENHANCED ULTRASOUND AND ELASTOGRAPHY IN IMAGING OF PROSTATE CANCER.

Pallwein L, Mitterberger M, Gradl J, Aigner F, Horninger W, Strasser H, Bartsch G, zur Nedden D, Frauscher F. (Department of Radiology II, Medical University Innsbruck, Austria.)

PURPOSE OF REVIEW: Prostate cancer is the most commonly diagnosed malignancy in men. Gray-scale ultrasound-guided systematic biopsy is the standard of care for prostate cancer detection in men with an elevated prostate-specific antigen or an abnormal digital rectal examination. Systematic biopsy may miss up to 35% of clinically relevant cancers. Color and power Doppler ultrasound, ultrasound contrast agents, and elastography have and will dramatically change the role of ultrasound in prostate cancer diagnosis.

RECENT FINDINGS: Several reports have demonstrated that contrast-enhanced ultrasound investigations of the blood flow of the prostate allow for prostate cancer visualization and therefore, for targeted biopsies. Comparisons between systematic and contrast-enhanced ultrasound-targeted biopsies have shown that the targeted approach detects more cancers with a lower number of biopsy cores. Furthermore, contrast-enhanced ultrasound has been shown to detect cancers with higher Gleason scores compared with the systematic approach, which seems to improve prostate cancer grading. In addition, elastography is a new ultrasound technique that allows for the assessment of tissue elasticity.

11-06-10

SUMMARY: Contrast-enhanced ultrasound and elastography improve prostate cancer detection and may be useful for prostate cancer grading and staging. Future clinical trials will be needed to determine the promise of these new advances for ultrasound of the prostate evolving into clinical applications.

Curr Opin Urol. 2007 Jan;17(1):39-47.

COMPARISON OF SONOELASTOGRAPHY GUIDED BIOPSY WITH SYSTEMATIC BIOPSY: IMPACT ON PROSTATE CANCER DETECTION.

Pallwein L, Mitterberger M, Struve P, Horninger W, Aigner F, Bartsch G, Gradl J, Schurich M, Pedross F, Frauscher F. (Department of Radiology 2/Uroradiology, Medical University Innsbruck, Anichstrasse 35, 6020, Innsbruck, Austria, leo.pallwein@i-med.ac.at.)

A prospective study was performed to determine the value of sonoelastography (SE) targeted biopsy for prostate cancer (PCa) detection. A series of 230 male screening volunteers was examined. Two independent examiners evaluated each subject. One single investigator performed ≤ 5 SE targeted biopsies into suspicious regions in the peripheral zone only. The stiffness of the lesion was displayed by SE and color-coded from red (soft) to blue (hard). Hard lesions were considered as malignant and targeted by biopsy. Subsequently, another examiner performed ten systematic biopsies. Cancer detection rates of the two techniques were compared. Cancer was detected in 81 of the 230 patients (35%), including 68 (30%) by SE targeted biopsy and in 58 (25%) by systematic biopsy. Cancer was detected by targeted biopsy alone in 23 patients (10%) and by systematic biopsy alone in 13 patients (6%). The detection rate for SE targeted biopsy cores (12.7% or 135 of 1,109 cores) was significantly better than for systematic biopsy cores (5.6% or 130 of 2,300 cores, $P < 0.001$). SE targeted biopsy in a patient with cancer was 2.9-fold more likely to detect PCa than systematic biopsy. SE targeted biopsy detected more cases of PCa than systematic biopsy, with fewer than half the number of biopsy cores in this prostate-specific antigen screening population.

Eur Radiol. 2007 Sep;17(9):2278-85

SONOELASTOGRAPHY OF THE PROSTATE: COMPARISON WITH SYSTEMATIC BIOPSY FINDINGS IN 492 PATIENTS.

Pallwein L, Mitterberger M, Pinggera G, Aigner F, Pedross F, Gradl J, Pelzer A, Bartsch G, Frauscher F. (Department of Radiology 2/Uroradiology, Medical University Innsbruck, Anichstrasse 35, A-6020 Innsbruck, Austria.)

OBJECTIVE: The aim of this study was to assess the value of sonoelastography (SE) for prostate cancer detection in comparison with systematic biopsy findings.

MATERIAL AND METHODS: Four hundred and ninety two PSA screening volunteers (mean age: 61.9 ± 8.6) with an total PSA $> 1.25 \text{ ng/mL}$ and a free to total PSA ratio of $< 18\%$ underwent SE of the prostate before 10 core systematic prostate biopsy. Tissue elasticity of the peripheral zone was investigated only. Tissue elasticity was displayed from red (soft) to green (intermediate) and to blue (hard). Only hard lesions (blue) were considered to be suspicious for prostate cancer. The peripheral zone of the prostate was divided in 3 regions on each side: base, mid-gland, apex. A different investigator performed systematic biopsy, and the biopsy findings were compared with the SE findings.

RESULTS: In 125 of 492 patients (25.4%) systematic biopsy demonstrated prostate cancer. Cancer was detected in 321 of 2952 (11%) outer gland areas (74 in the base, 106 in the mid-gland, 141 in the apex). The Gleason score ranged from 3 to 10 (mean: 6.5). In SE 533 of 2952 (18.1%) suspicious

areas were detected and 258 of these areas (48.4%) showed cancer. Most of the false-positive findings (275/533 areas; 51.6%) were associated with chronic inflammation and atrophy especially at the basal prostate areas. The sensitivity by entire organ was calculated with 86% and the specificity 72%. The analysis by outer gland areas showed the highest sensitivity in the apex (79%). The specificity by outer gland areas ranged between 85% and 93%. The correlation between SE findings and biopsy results was high ($p < 0.001$).

CONCLUSION: Sonoelastography findings showed a good correlation with the systematic biopsy results. The best sensitivity and specificity was found in the apex region. Sonoelastography seems to offer a new approach for differentiation of tissue stiffness of the prostate and may therefore improve prostate cancer detection.

Eur J Radiol. 2008 Feb;65 (2):304-10

ASSESSMENT OF PEYRONIE DISEASE BY SONOELASTOGRAPHY: PRELIMINARY RESULTS

Gerhard M Pinggera, Leo Pallwein, MD, Fritz Aigner, MD, Ferdinand Frauscher, MD, PhD, Michael Mitterberger, MD, Nicolai Leonhartsberger, Hannes Strasser, Georg Bartsch, MD. Medical University Innsbruck, Innsbruck, Austria

Introduction and Objective: With a reported prevalence of 400 per 100,000 the Peyronie disease (PD) compromises male sexual function due to penile deformity and altered rigidity. To assess the extent of the penile scar investigations with MRI or ultrasound (US) are widely employed. However, it is often difficult to estimate the plaque extension in the interseptal part with US, particularly in plaques without clear calcification areas. The aim of the present preliminary study was to evaluate the usefulness of sonoelastography (SE-US) for assessing the extension of PD in the interseptal part of the penis.

Methods: Between 01/06 and 08/06, a total of 16 patients with PD (mean age 43.2 years ± 16.6) were referred to our hospital and evaluated by means of conventional B-mode US with an Acuson Sequoia 512 unit (high frequency linear probe; LW15). Penile plaques were documented in biaxial diameters. Furthermore, all patients underwent a SE-US examination, performed by another blinded examiner, with a Hitachi 8500 US unit. SE-US is able to display tissue stiffness in different colors. In case of PD, areas of increased tissue stiffness are displayed in blue.

Results: By clinical examination, plaque detection rate was 12/16 (75%). Using conventional US, plaques could be detected in the distal penis in 4 patients, in the middle in 6, in the proximal penis in 3, and in the interseptal region in 2 patients. The plaque pattern was multilocal in 8 and calcification involvement was found in 10. In 1 patient with proven 45° dorsal deviation after pharmacologically induced erection, no scar tissue could be found. The SE-US examination confirmed all of the 15 plaques detected by conventional sonography; furthermore, it also revealed a septal fibrotic lesion in the patient with pharmacologically induced erection, which conventional sonography failed to detect. Finally, the detection sensitivity for all 3 patients with interseptal localization was superior with detailed visualization of disease-specific alterations. Plaque extension comparisons showed higher-grade lesions, underestimated by conventional B-mode sonography.

Conclusions: This preliminary study demonstrates the feasibility and accuracy of SE-US investigations in detection and visualization of scar formation in PD patients. By applying SE-US measurements, the detection rate of fibrotic lesions is improved, especially of those with interseptal location, which provides a diagnostic advantage over conventional sonography to clinicians assessing penile scars responsible for impaired sexual function.

American Urological Association Annual Meeting, May 19th -24th, 2007, Anaheim, USA

SONOELASTOGRAPHY IN EVALUATING MALE URETHRAL STRICTURES

Michael Mitterberger, MD, Germar M Pinggera, MD, Christian Gozzi, MD, Ferdinand Frauscher, MD, Leo Pallwein, MD, Johann Gradl, MD, Georg Bartsch, MD, Hannes Strasser, MD. Medical University Innsbruck, Innsbruck, Austria

Introduction and Objective: It was the aim of the present study to compare the clinical relevance of radiourethrography (RUG) with sonoelastography (SE) in evaluation of male urethral strictures.

Methods: 42 men were referred to our institute for management of anterior urethral strictures. The patients were investigated by conventional radiourethrography (RUG) and sonoelastography (SE). SE was used to obtain images of the anterior urethra and to evaluate the tissue elasticity of the urethra. Tissue elasticity was displayed from red (soft) over green (intermediate) to blue (hard). All strictures were evaluated and treated either cystoscopically (visual internal urethrotomy) or with open surgery. During surgery the length of the stricture was measured and compared with the RUG and SE findings.

Results: In all 42 men RUG yielded 2 false-negative results and 1 false-positive result. The mean stricture length as measured by RUG was 1.6 \pm 1.1 cm and by SE was 2.5 \pm 0.5 cm (correlation coefficient = 0.71 versus 0.95, $p < 0.005$). In the penile urethra the correlation coefficient for both modalities was good (0.91 for RUG and 0.98 for SE) in comparison with the stricture lengths measured at operation. In the bulbar urethra RUG showed a poor correlation (0.65) versus a good correlation for SE (0.95). SE correctly identified all strictures of the anterior urethra. Especially with the B-mode the extension of the scar tissue in the corpus spongiosum could be evaluated precisely. SE in conjunction with CDUS permitted identification of spongiofibrosis and the vascular integrity of the spongiosal tissue. Further SE allowed directly visualization of the spongiofibrosis.

Conclusions: The present data demonstrate that sonoelastography allows for detection of anterior urethral strictures, precise measurement of stricture size and direct characterization of the spongiofibrosis. SE allows a better estimation of the pathological stricture length and therefore improved planning for surgery.

American Urological Association Annual Meeting, May 19th -24th, 2007, Anaheim, USA

CAN REAL-TIME TRANSRECTAL ELASTOGRAPHY IN COMBINATION WITH POWER DOPPLER SONOGRAPHY ENHANCE PROSTATE CANCER DETECTION?

Koji Okihara, Kazumi Kamoi, Atsushi Ochiai, Osamu Ukimura, S Ushijima, Yoichi Mizutani, Akihiro Kawauchi, Tsuneharu Miki. Kyoto Prefectural University of Medicine, Kyoto, Japan

Introduction and Objective: Currently, prostate biopsies technique using real-time transrectal elastography (TREG) as well as conventional B mode image was reported (KÖNIG et al J Urol, 115, 2005), and TREG contributed to enhance prostate cancer detection. In addition, vascular investigation inside the prostate using transrectal power Doppler sonography (TRPDS) was also reported to enhance cancer detection (OKIHARA et al, J Clin Ultrasound, 213, 2002). Current ultrasound system enabled us to survey the prostate using TREG and TRPDS simultaneously. The aim of this study is to clarify whether real-time TREG in combination with TRPDS enhance prostate cancer detection.

Methods: Since March 2005, 108 men with suspicious digital rectal examination (DRE) findings and/or increased prostate specific antigen (PSA) whose value was less than 20 ng/ml underwent conventional transrectal B-mode ultrasound (TRUS), TRPDS and TREG sequentially prior to prostate biopsy. A EUB-6500 ultrasound system (Hitachi Medical/Chiba, Japan) was used during the study with a 5.0 and 7.5 MHz bi-plane transrectal probe. TRPDS signals were graded on the scale based on Doppler vascular accumulations. TREG images were assigned an elasticity score according to the degree and distribution of strain induced by light compression. To assess the clinical utility of those

imaging modalities, we compared the values of overall diagnostic accuracy of TRUS, TRPDS and TREG based on the biopsy outcomes.

Results: In 40 of 108 patients (37%) the diagnosis of prostate cancer was histologically confirmed. The diagnostic performances of each imaging modality as well as DRE were shown in the table. There were no significant diagnostic improvements using TREG compared with other imaging modalities. However, the sensitivity for TREG in combination with TRPDS (75%) revealed 5% improvement compared to TRPDS alone. Conclusions: Although the diagnostic performance of TREG was almost identical to that of TRPDS, those combinations enhanced prostate cancer detection.

American Urological Association Annual Meeting, May 19th -24th, 2007, Anaheim, USA

THE PATIENT WITH ELEVATED PSA: WHEN AND HOW TO USE MULTIMODALITY IMAGING - HOW CAN US HELP?

F. Frauscher; *Innsbruck/AT*

In patients with an elevated PSA, grey-scale ultrasound (US) guided "systematic" biopsy is the current standard of care for prostate cancer detection. Unfortunately, systematic biopsy has shown to miss a significant number of clinically relevant cancers, even with the use of up to 24 biopsy cores.

Therefore, new US techniques have been introduced to improve cancer detection. Cancer generally grows more rapidly than normal tissue and demonstrates an increased blood flow, as compared to normal tissue and benign lesions. Contrast-enhanced color Doppler US and grey-scale harmonic imaging allow for exact assessment of tumour vascularity and therefore may improve cancer detection. The degree of vascularity has shown to some potential in grading prostate cancer. Sonoelastography is a new technique, which allows for assessment of tissue elasticity, and since cancer has shown to be stiffer than the normal tissue, this technique seems to have potential in prostate cancer detection and differentiation between cancer and benign lesions. Furthermore, this new technique enables good visualisation of the prostate capsule, and may have a new potential in staging of prostate cancer. In addition, image fusion between magnetic resonance imaging (MRI) and US may allow for targeted biopsies with real-time US into suspicious areas detected on MRI. In summary, these new US imaging techniques show improvement in prostate cancer detection, grading and staging, and are useful in men presenting with an elevated PSA.

Learning Objectives:

1. To show how state-of-the-art TRUS of prostate cancer should be performed.
2. To show the role of TRUS in detection and local staging, and evaluation of recurrences.
3. To show the value of new developments in TRUS of prostate cancer.

European Congress of Radiology, March 9th – 12th 2007, Vienna, Austria

SONOELASTOGRAPHY OF THE PROSTATE: COMPARISON WITH SYSTEMATIC BIOPSY FINDINGS IN 492 PATIENTS

E. Pallwein, L. Pallwein, F. Aigner, V. Fischbach, D. zur Nedden, F. Frauscher; *Innsbruck/AT*

Purpose: The aim of this study was to assess the value of sonoelastography (SE) for prostate cancer detection in comparison with systematic biopsy findings.

Methods and Materials: 492 volunteers (mean age: 61.9 ± 8.6) with a total PSA > 1.5 ng/mL underwent SE of the prostate before 10 core systematic prostate biopsies. The outer gland was divided in 3 regions on each side: base, mid-gland, apex. During SE tissue elasticity was displayed from red (soft) to blue (hard). Hard lesions were considered as malignant. Biopsy findings of the outer gland areas were compared with the SE findings.

Results: 125 patients (25.4%) demonstrated prostate cancer on systematic biopsy. Cancer was detected in 321/2952 (11%) outer gland areas (74 in the basis, 106 in the mid-gland, 141 in the apex). The Gleason score ranged from 3 to 10 (mean: 6.5). In SE 533/2952 (18.1%) suspicious areas were detected and 258 of these areas (48.4%) showed cancer. Most of the false-positive findings (275/533 areas; 51.6%) were associated with inflammation and atrophy. The sensitivity by entire organ was

calculated with 0.86 and the specificity 0.72. The analysis by outer gland areas showed the highest sensitivity in the apex (0.79). The specificity ranged between 0.85 and 0.93. The correlation between SE findings and biopsy results was high ($p < 0.001$).

Conclusion: Sonoelastography findings showed a good correlation with the systematic biopsy results. The best sensitivity and specificity was found in the apex region. Sonoelastography seems to offer a new approach for differentiation of tissue stiffness of the prostate and may therefore improve prostate cancer detection.

European Congress of Radiology, March 9th – 12th 2007, Vienna, Austria

PROSTATE CANCER AND EXTRACAPSULAR EXTENSION (ECE): ASSESSMENT BY SONOELASTOGRAPHY IN COMPARISON WITH MRI - A PRELIMINARY STUDY

F. Aigner, L. Pallwein, E. Pallwein, M. Schurich, D. zur Nedden, F. Frauscher; *Innsbruck/AT*

Purpose: Sonoelastography (SE) can detect prostate cancer and is also able to delineate prostate capsule as a soft rim artefact. The goal was to compare SE to structural MRI for assessment of organ exceeding growth (ECE) of prostate cancer.

Methods and Materials: In 15 patients with clearly elevated PSA (mean: 21 ± 9), SE was performed for cancer detection and delineation of the prostate capsule. Tumor tissue is displayed as stiff area and prostate capsule is delineated by a "soft rim artefact". At the site of ECE, this sign is interrupted. SE was compared with T2w and contrast enhanced T1w MRI images and to the histopathologic findings after radical prostatectomy (RPE).

Results: RPE showed ECE in 11 of 15 patients including infiltration of the capsule with extent into fat tissue in 9 cases and into the seminal vesicles in 5 cases. Cancer areas could be well detected with SE in all patients. SE showed infiltration of the capsule in 8 patients and an increased stiffness of seminal vesicles in 4 cases. MRI was able to delineate cancer areas in all cases and showed signs of infiltration of the periprostatic fat tissue clearly in 7 cases. An infiltration of the seminal vesicles could be detected with MRI in 5 cases.

Conclusion: Sonoelastography detected all cancer areas. On the other hand, this method was able to delineate the prostate capsule and showed remarkable strength in the prediction of ECE. These results correlated well with MRI and histopathologic findings.

European Congress of Radiology, March 9th – 12th 2007, Vienna, Austria

HOW CAN IMAGING IMPROVE PROSTATE BIOPSY?

F. Frauscher, L. Pallwein; *Innsbruck/AT*

Grey-scale ultrasound (US) guided "systematic sextant" biopsy is the current standard of care for detection of prostate cancer in patients with an elevated PSA and/or abnormal digital rectal examination (DRE). Unfortunately, this approach has shown to miss up to 35% of clinically relevant cancers. Consequently, the number of cores has been increased to improve cancer detection; however, several studies have shown no significant improvement in cancer detection. Since it is well known that cancerous tissue generally grows more rapidly than normal tissue and demonstrates an increased blood flow, as compared to normal tissue, new imaging techniques have been studied, which can assess tumour vascularity. Such new US techniques include colour and power Doppler US, and the application of US contrast agents with contrast-specific US techniques, such as grey-scale harmonic imaging. These techniques may dramatically change the role of US for prostate cancer detection. Studies have shown that contrast-enhanced US allows for targeted biopsies, and can significantly improve cancer detection when compared with systematic biopsy. In addition, elastography or "strain imaging" seems to have a great potential for targeting biopsies into areas with higher stiffness. Virtual navigation tools allow for image fusion between MRI and US, which allows for targeted biopsies with real-time US into suspicious areas detected on MRI. These new imaging

techniques allow for prostate cancer visualization, and thus for targeted biopsies and may, therefore, replace the "gold standard" for prostate cancer detection - the systematic biopsy.

Learning Objectives:

1. To show how new ultrasound techniques (i.e. contrast agents, elastography, texture analysis) can improve visualisation of prostate cancer.
2. To show the role of image-guided biopsies for prostate cancer diagnosis and therapy.
3. To show future developments such as targeted contrast agents for ultrasound imaging of prostate cancer.

European Congress of Radiology, March 9th – 12th 2007, Vienna, Austria

COMPARISON OF SONOELASTOGRAPHY GUIDED BIOPSY WITH SYSTEMATIC BIOPSY: IMPACT ON PROSTATE CANCER DETECTION

L. Pallwein, F. Aigner, E. Pallwein, V. Fischbach, J. Gradl, F. Frauscher; *Innsbruck/AT*

Purpose: We performed a prospective study to determine whether a limited biopsy approach with sonoelastography (SE) targeted biopsy of the prostate would detect cancer as well as gray scale US guided systematic biopsy with a larger number of biopsy cores.

Methods and Materials: We examined 230 men (mean age: 62.3) with a total PSA of 1.25 ng/ml or greater. First investigator performed 5 or fewer SE targeted biopsies into suspicious (stiffer) regions in the peripheral zone. Hard lesions were considered as malignant. Subsequently, another examiner performed 10 systematic prostate biopsies. The cancer detection rates of the 2 techniques were compared.

Results: Cancer was detected in 81 of the 230 patients (35%), including 68 (30%) by SE targeted biopsy and in 58 (25%) by systematic biopsy. The overall cancer detection rate by patient was not significantly different for SE targeted and systematic biopsy ($p = 0.132$). The detection rate for SE targeted biopsy cores (12.7% or 135 of 1,109 cores) was significantly better than for systematic biopsy cores (5.6% or 130 of 2,300 cores, $p < 0.001$). SE targeted biopsy in a patient with cancer was 2.9-fold more likely to detect prostate cancer than systematic biopsy.

Conclusion: Sonoelastography targeted biopsy detected as many cancers as systematic biopsy with fewer than half the number of biopsy cores. Although an increase in cancer detection was achieved by combining targeted and systematic techniques in this screening population, Sonoelastography targeted biopsy alone is a reasonable approach for decreasing the number of biopsy cores.

European Congress of Radiology, March 9th – 12th 2007, Vienna, Austria

SONOELASTOGRAPHY MAKES HEADWAY IN PROSTATE CANCER ASSESSMENT

Diagnostic Imaging Webcast, ECR 2007

By: Emily Hayes

Sonoelastography shows strong performance in prostate cancer detection, but room for improvement remains when it comes to specificity, according to research from the Medical University Innsbruck in Austria, a leading center in prostate imaging research.

Sonoelastography has been in research stages for many years but has only recently approached the verge of entering clinical practice. The technique uses ultrasound to measure the elastic properties of tissues, based on the well established principle that malignant tissue is harder than benign tissue. A color classification system registers tissue as benign (green) or malignant (blue).

Prostate cancer is one of the most common cancers in men. As diagnostic testing with the prostate-specific antigen blood test has increased, so have the number of biopsies, with a high rate of negative results. Typically, biopsies are performed by urologists guided by gray-scale ultrasound, which suffers from low sensitivity.

The release of two new software upgrades in the last year and the availability of more effective probes have enhanced sonoelastography's performance in prostate imaging, according to Dr. Ferdinand Frauscher, director of uroradiology at Medical University Innsbruck.

"We now have tools that provide better imaging information about tissue elasticity and enable better detection of suspicious lesions," said Frauscher in an interview with *Diagnostic Imaging*.

At the conference on Monday, Innsbruck researchers presented two new papers about the technique's role in prostate imaging, based on results with a Hitachi ultrasound system. In the first study of almost 500 patients, they found a very high correlation between sonoelastography and systematic biopsy results.

Patients involved in the study had a PSA level over 1.5 ng/mL and underwent 10-core systematic biopsy. To overcome the challenge of getting adequate compression of the entire gland, the Austrian researchers use a narrower region of interest, examining the prostate in three sections: base, mid gland, and apex.

According to systematic biopsy results, 125 patients had cancer. There were 321 cancerous areas, with Gleason scores ranging from 3 to 10. Confirmed results on biopsy showed that sonoelastography had very good sensitivity of 86% for the entire prostate organ but lower specificity of 72%. Of 533 findings, the technique identified 275 false positives, due to mistaken assessments of areas with inflammation and atrophy. Sonoelastography performed best in cancers of the apex, with sensitivity of 79% and specificity of 85% to 93%. Performance was weakest in cancers located in the base of the organ. "The results are promising, especially in atypical areas," said Dr. Leo Pallwein, who presented results.

Another study from the same institution suggests sonoelastography can help determine whether cancer has spread beyond the capsule of the prostate gland (extracapsular extension). Making such a determination is crucial for selecting the most appropriate treatment for the patient.

Researchers performed sonoelastography and obtained contrast-enhanced T1- and T2-weighted MR images in 15 patients with elevated PSA levels prior to radical prostatectomy. Spectroscopy and image fusion were not performed with MR. Based on the histopathologic results, all cancers were well visualized with both sonoelastography and MRI. Surgery results indicated extracapsular extension in 11 of 15 cases.

Sonoelastography showed infiltration of the capsule in eight patients and stiffness in seminal vesicles in four cases. MRI showed infiltration in the periprostatic fat tissue in seven cases and infiltration of the seminal vesicles in five cases.

"Sonoelastography correlated well with MRI and histologic findings. It showed remarkable strength for prediction of extracapsular extension," said Dr. Friedrich Aigner, who presented study results.

NEW TECHNIQUES PROMISE BETTER DETECTION OF PROSTATE CANCER

Diagnostic Imaging Webcast, ECR 2007

Frances Rylands-Monk

Ultrasound techniques that are improving prostate cancer detection, grading, and staging are useful in men presenting with an elevated level of prostate specific antigen. They offer therapeutic strategies and may avoid the need for prostatectomy. In the future, surgery may not be the number one treatment choice, according to speakers at a special focus session on imaging in patients with elevated PSA levels.

Using real-time elastography, tissues can be compressed by a probe to measure their stiffness. Studies reveal that real-time sonoelastography-targeted biopsy in a patient with cancer is 2.8 times more likely to reveal prostate cancer than systematic ultrasound-guided biopsy.

Elastography also shows potential in staging the disease. While some questions remain about its limitations in terms of cost, training, and potential delivery of false-positive results related to medication or prostatitis, the technique looks set to become another standard technique requested of the radiologist by the clinician.

Part of the battle is detection of the cancer, according to Dr. Ferdinand Frauscher of the Medical University of Innsbruck in Austria. Gray-scale ultrasound provides useful information on the anatomy and morphology of the prostate and high differentiation between the peripheral zone and the inner gland.

In the early 1980s, hypoechoic nodules were seen as the main presentation of prostate cancer, but up to 30% of all prostate cancers are isoechoic. Frauscher estimates that hypoechoic nodules have a 17% to 57% chance of being identified as prostate cancer, though since the discovery of PSA, this percentage is reported to be as low as 9%.

Gray-scale ultrasound remains a key tool for guiding biopsies and other interventions, but it misses a number of clinically relevant cancers due to its relatively low sensitivity and specificity. New methods can dramatically improve diagnosis and grading, according to Frauscher. Besides elastography, contrast-enhanced color Doppler lends weight to staging due to its ability to demonstrate vascularity.

While vascular patterns demonstrated by color Doppler flow detect advanced disease, a considerable number of cancers are missed even with high-end Doppler units. Contrast enhancement shows an increased sensitivity and specificity in studies carried out at the university hospital and increases identification of malignant lesions with higher Gleason scores.

Prostate cancer has a high incidence rates, accounting in 2003 for one in three cancers detected in the U.S. and one in five in the Netherlands. Despite an increase in prostate cancer detection since the discovery of PSA in 1991, a flat mortality rate suggests that most patients have a good chance of survival if the cancer is caught and followed through prostatectomy, radiation therapy, active surveillance, or watchful waiting.

In T1 tumors treated locally and T4s requiring radiation therapy, the tumor's exact location and size are pivotal to accurate staging and choice of therapy. Removal of a T1 is followed by an average 70% to 80% 10-year survival rate, according to Dr. Jeroen van Moorselaar, a urologist at the Vrije Universiteit Medisch Centrum in Amsterdam. These days, though, patients demand more than simply survival.

"Side effects such as incontinence and impotence, if the neurovascular bundles are cut, are no longer acceptable to many patients. The radiologist can tell the surgeon the location of the tumor in the peripheral zone, which is important for prognosis of side effects after surgery," Moorselaar said.

TISSUE ELASTICITY IMAGING FOR DIAGNOSIS OF PROSTATE CANCER: A PRELIMINARY REPORT.

Miyanaga N, Akaza H, Yamakawa M, Oikawa T, Sekido N, Hinotsu S, Kawai K, Shimazui T, Shiina T.

Department of Urology, Graduate School of Comprehensive Human Sciences, Tsukuba, Japan. nao-miya@md.tsukuba.ac.jp

BACKGROUND: Elastography is a diagnostic imaging technique that evaluates the hardness of a lesion. It is expected to become a new diagnostic modality for prostate cancer. The aim of this study was to examine the usefulness of elastography in the diagnosis of prostate cancer. **METHODS:** A total of 29 patients with untreated, histologically proven prostate cancer were examined using an elastographic imaging technique. The patient was scanned in the dorsosacral position and the prostate was manually compressed with a transrectal ultrasonic probe. The echo signals from inside the tissue were measured before and after the tissue compression and an elastogram was generated by spatially differentiation of the displacement distribution. **RESULTS:** Elastography depicted the cancer lesion as a harder tissue than the surrounding normal prostatic tissue. Elastography successfully detected 93% (27 patients) of the untreated prostate cancer lesions. Detection of cancer lesions using elastography was significantly higher than by digital rectal examination (59%; 17 patients) and transrectal ultrasonography (55%; 16 patients). **CONCLUSION:** Elastography has great potential as a useful modality for diagnosis of prostate cancer. Differentiation between cancerous and normal tissues can be expected to become more accurate as a result of technical advances in the quantification of tissue hardness.

Int J Urol. 2006 Dec;13(12):1514-8.

EARLY PROSTATE CANCER DETECTION: SONOELASTOGRAPHY AND ENDORECTAL MRI-GUIDED TARGETED BIOPSY

Pallwein L, Aigner F, Gradl J, Judmaier W, Zur Nedden D, Frauscher F, Innsbruck AUSTRIA

PURPOSE

To assess the value of SonoElastography for detection of early prostate cancer in comparison to endorectal MRI.

METHOD AND MATERIALS

Fifty patients with elevated PSA blood values (ranging from 1.5 to 6.0) were examined with endorectal SonoElastography (Examiner 1; Hitachi), during which the elasticity of prostate tissue was displayed from red (soft) to blue (hard). Hard lesions were considered as malignant. The findings of SonoElastography were compared with T2w and contrast enhanced T1w endorectal MRI images (Examiner 2; Siemens, 1.5T). Suspicious areas were divided in 3 groups. Group A: tissue changes in both methods, Group B: changes in SonoElastography alone, Group C: changes in MRI alone. All these areas were selected for US guided targeted prostate biopsy with 2 cores from each lesion. Subsequently systematic biopsy was performed.

RESULTS

Overall 87 areas (174 cores) were selected in Group A, 24 in Group B (48 cores), and 14 in Group C (28 cores) for targeted biopsy. Targeted biopsy detected cancer in 18/50 patients (Gleason 5-7), whereas the systematic biopsy detected cancer in 14 patients. In Group A 32 cores (18%) were positive for cancer, in Group B 6 cores (13%), in Group C 4 cores (12%) and in the systematic biopsy 31/500 cores (6%).

CONCLUSION

With the limitation of a small study population SonoElastography combined with MRI seems to be able to enhance visualization of early prostate cancer.

CLINICAL RELEVANCE/APPLICATION

SonoElastography is able to improve prostate cancer detection.

Radiological Society of North America 92nd Scientific Assembly and Annual Meeting November 26th – December 1st, 2006, Chicago, USA

ELASTOGRAPHY UNDERGOES REVIEW FOR PROSTATE CANCER DETECTION

Diagnostic Imaging Europe, August/September 2006

Elastography is attracting growing attention in prostate imaging. The term refers to the measurement of the elastic properties of tissues, based on the well-established principle that malignant tissue is harder than benign tissue. A color classification system registers tissue as benign (green) or malignant (blue).

A raw ultrasound is obtained before and after a slight compression of tissue, typically achieved with an ultrasound transducer. Elastography measures and displays strain, or the change in the dimension of tissue elements at various locations in the region of interest.

Dr. Ethan Halpern, a professor of radiology and urology at Thomas Jefferson University in Philadelphia, Pennsylvania, performed a trial of 137 patients, in which targeted biopsy with Doppler and elastography improved prostate cancer detection but missed a substantial minority of cancers found on systematic sextant biopsy. "Success depends on applying pressure evenly to prostate, and that is difficult to achieve with current systems," Halpern said.

Researchers in Austria have been working to overcome the technique's limitations. To make compression easier, for example, they use a narrower region of interest, examining the right, middle, and left parts of the prostate. This technique significantly improves overall accuracy but is much more time consuming, said Dr. Ferdinand Frauscher, director of urology at the Medical University Innsbruck. Frauscher shared his experience with elastography at the 2006 European Congress of Radiology.

A software technique that assigns elasticity coefficient values for the stiffness of tissues, in addition to the color values, is also proving useful. The coefficient values offer a more objective measure of malignancy than do the colors, Frauscher said.

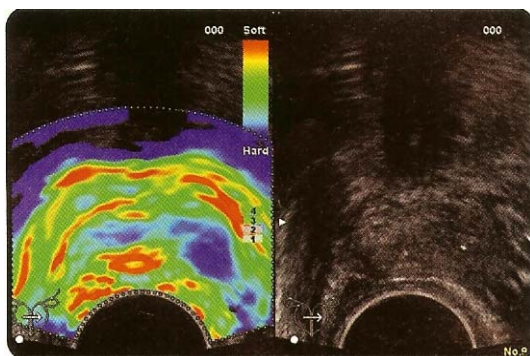
Results of a new unpublished study of elastography in 100 patients are encouraging. Radiologists obtained elastography images and performed a targeted biopsy if an abnormality was detected. They found cancer in 36 of 100 (36%) patients with a mean PSA of 4.1. Results were compared with systematic biopsy. Elastography detected cancer in 29 subjects, and systematic biopsy found cancer in 26 subjects. Elastography had a sensitivity of 81 % and specificity of 84%.

"The results are better than expected," Frauscher said.

Some cancers are still missed, however, such as those located in the anterior prostate and small masses. Frauscher noted that his results may not apply across the board, because he is working with a screening population. Patients in prostate screening programs tend to be younger with smaller glands, which are easier to examine with elastography. The technique is performed only in first biopsies, where it may be more effective.

Frauscher and Halpern agree that in coming years radiologists will play a greater role in prostate imaging, because techniques like contrast-enhanced ultrasound and elastography require a higher skill level. Ultrasound is the workhorse for prostate imaging, although interesting work is under way with high-field MR and MR spectroscopy imaging. .

-By Emily Hayes



Elastography color classification system registers tissue as benign (green) or malignant (blue). Cancer is on left side. Grayscale ultrasound is negative, but elastography shows stiffer cancer area as blue (malignant). (Provided by F. Frauscher)

COMPARISON OF REAL-TIME ELASTOGRAPHY TARGETED BIOPSY WITH CONVENTIONAL SYSTEMATIC BIOPSY: IMPACT ON PROSTATE CANCER DETECTION

Ferdinand Frauscher, Leo Pallwein, Friedrich Aigner, Andreas Paul Berger, Alexander Pelzer, Wolfgang Horninger, Georg Bartsch, Innsbruck, Austria

Introduction and Objective: We performed a prospective study to determine whether a limited biopsy approach with real-time elastography targeted biopsy of the prostate would detect cancer as well as gray scale ultrasound (US) guided systematic biopsy with a larger number of biopsy cores. **Methods:** We examined 100 male screening volunteers with a total prostate specific antigen of 1.25 ng./ml. or greater and free-to-total prostate specific antigen less than 18%. Two independent examiners evaluated each subject. One investigator performed 5 or fewer real-time elastography targeted biopsies into areas with a high tissue stiffness in the peripheral zone using an 8500 US system (Hitachi, Medical Systems). Subsequently another examiner performed 10 systematic prostate biopsies. The cancer detection rates of the 2 techniques were compared.

Results: Cancer was detected in 34 of the 100 patients (34%), including 25 (25%) by real-time elastography and in 23 (23%) by systematic biopsy. Cancer was detected by real-time elastography alone in 8 patients (8%) and by systematic biopsy alone in 6 (6%). The overall cancer detection rate by patient was not significantly different for targeted and systematic biopsy ($p = 0.57$). The detection rate for targeted biopsy cores (11.3% or 49 of 432 cores) was significantly better than for systematic biopsy cores (6.2% or 62 of 1000 cores, $p < 0.001$). Real-time elastography targeted biopsy in a patient with cancer was 2.8-fold more likely to detect prostate cancer than systematic US guided biopsy.

Conclusions: Real-time elastography targeted biopsy detected slightly more cancers as systematic biopsy with fewer than half the number of biopsy cores in this screening population. Therefore this technique is a reasonable approach for decreasing the number of biopsy cores.

American Urological Association Annual Meeting, May 20 - 25, 2006, Atlanta, USA

IMAGING OF PROSTATE CANCER: HOW CAN IMAGING IMPROVE PROSTATE BIOPSY?

F. Frauscher; *Innsbruck/AT*

The current standard of care for the detection of prostate cancer in patients with an elevated PSA and/or abnormal digital rectal examination is grey-scale ultrasound (US) guided "systematic sextant" biopsy. Unfortunately, this technique has shown to miss up to 35% of clinically relevant cancers. Subsequently the number of cores has been increased to improve cancer detection, however several studies have shown no significant improvement in cancer detection. To increase cancer detection new imaging techniques have been studied, which can assess tumour vascularity, since it is well known that cancerous tissue generally grows more rapidly than normal tissue and demonstrates an increased blood flow, as compared to normal tissue and benign lesions. Such new US techniques include colour and power Doppler US and the application of US contrast agents with contrast specific US techniques, such as grey-scale harmonic imaging, which has dramatically changed the role of US for prostate cancer detection. Several studies have shown that contrast enhanced US allows for targeted biopsies and can significantly improve cancer detection when compared with systematic biopsy. Furthermore elastography or "strain imaging" seems to have a great potential in prostate cancer detection. Virtual navigation tools allow for an image fusion between MRI images and US, which allows for targeted biopsies with real-time US into suspicious areas detected on MRI. These current trends show that these new imaging techniques allow for prostate cancer visualisation and thus for targeted biopsies and can therefore replace the current "gold standard" for prostate cancer detection-the systematic biopsy.

1. To show how new ultrasound techniques (i.e. contrast agents, elastography) can improve visualization of prostate cancer.
2. To show the role of image-guided targeted biopsies for prostate cancer diagnosis and therapy.
3. To show future developments such as image fusion of ultrasound and MR imaging.

European Congress of Radiology, March 3^d – 7th 2006, Vienna, Austria

COMPARISON OF REAL-TIME SONOELASTOGRAPHY TARGETED BIOPSY WITH CONVENTIONAL SYSTEMATIC BIOPSY: IMPACT ON PROSTATE CANCER DETECTION

Ferdinand Frauscher et al, Radiology Department, Medical University, Innsbruck, AUSTRIA.

PURPOSE: We performed a prospective study to determine whether a limited biopsy approach with real-time sonoelastography targeted biopsy of the prostate would detect cancer as well as gray scale ultrasound (US) guided systematic biopsy with a larger number of biopsy cores.

METHODS AND MATERIALS: We examined 100 male screening volunteers with a total prostate specific antigen of 1.25 ng./ml. or greater and free-to-total prostate specific antigen less than 18%. Two independent examiners evaluated each subject. One investigator performed 5 or fewer real-time sonoelastography targeted biopsies into areas with a high tissue stiffness in the peripheral zone using an 8500 US system (Hitachi, Medical Systems). Subsequently another examiner performed 10 systematic prostate biopsies. The cancer detection rates of the 2 techniques were compared.

RESULTS: Cancer was detected in 34 of the 100 patients (34%), including 25 (25%) by real-time sonoelastography and in 23 (23%) by systematic biopsy. Cancer was detected by real-time sonoelastography alone in 8 patients (8%) and by systematic biopsy alone in 6 (6%). The overall cancer detection rate by patient was not significantly different for targeted and systematic biopsy ($p =$

0.57). The detection rate for targeted biopsy cores (11.3% or 49 of 432 cores) was significantly better than for systematic biopsy cores (6.2% or 62 of 1000 cores, $p < 0.001$). Real-time sonoelastography targeted biopsy in a patient with cancer was 2.8-fold more likely to detect prostate cancer than systematic US guided biopsy.

CONCLUSION: Real-time sonoelastography targeted biopsy detected slightly more cancers as systematic biopsy with fewer than half the number of biopsy cores in this screening population. Therefore this technique is a reasonable approach for decreasing the number of biopsy cores.

Radiological Society of North America 91st Scientific Assembly and Annual Meeting, November 27th – 30th 2005, Chicago, USA

TO ASSESS THE VALUE OF SONOELASTOGRAPHY IN THE DIFFERENTIAL DIAGNOSIS OF INFLAMMATORY AND NEOPLASTIC DISEASES OF THE TESTICLES.

Leo Pallwein et al, Radiology Department, Medical University, Innsbruck, AUSTRIA

METHODS AND MATERIALS: In 15 patients suffering from scrotal pain and swelling a routine US examination (B-mode and color Doppler US) was performed (Acuson Sequoia, Mountainview, Ca). All patients underwent an additional qualitative measurement of tissue elasticity by using sonoelastography (Hitachi EUB-8500). These exams were performed by a different urologist, who was blinded to the results of routine sonography. The stiffness of the lesion was displayed from red (soft) to blue (hard). Hard lesions were considered as malignant. The diagnostic outcome of the two examinations was compared in each patient.

RESULTS: In 7 patients routine US was able to detect testicular masses of different size, which were histologically proven to be neoplastic lesions of different types (germ cell tumor, seminoma, teratoma, mixed tumors). Elastography was able to detect all these lesions and enabled the detection of two additional not well circumscribed lesions in a patient suspected to have tumor recurrence in a single testis. Elastography was also able to differentiate between inflammatory changes and testicular swelling in a patient suspected of diffuse lymphomatous infiltration based on the differences in tissue stiffness. Orchitis could be detected as a decrease in tissue elasticity comparing to normal testicles. **CONCLUSION:** Our preliminary findings showed that in patients with diffuse scrotal swelling and pain the sonoelastography improved the detection of testicular masses and allow the differentiation of inflammatory changes from other pathological processes based on the differences in tissue elasticity.

Radiological Society of North America 91st Scientific Assembly and Annual Meeting, November 27th – 30th 2005, Chicago, USA

TARGETED BIOPSY OF THE PROSTATE: UTILITY OF GRAY SCALE, COLOR DOPPLER, AND ELASTOGRAPHY FOR THE DETECTION OF PROSTATE CANCER

Ethan Halpern et al, Thomas Jefferson

PURPOSE: To evaluate a targeted biopsy approach for detection of prostate cancer based upon real time gray scale sonography, color Doppler and elastography.

METHODS AND MATERIALS: Eighty one patients referred for prostate biopsy were evaluated. Mean patient age was 65 years (range: 43-82 years). Mean serum prostate specific antigen was 8.4ng/dl (range: 1.9-47.3ng/dl). Imaging was performed with an end-fire transrectal probe (Hi-Vision 8500; Hitachi Medical Systems). Manual compression of the prostate with the probe was used to generate elastograms. Up to 6 targeted core biopsy specimens were obtained from areas of abnormal gray scale, increased color flow and decreased elasticity. Six laterally distributed systematic sextant biopsy specimens were obtained from all subjects. Gray scale, color Doppler and elastography findings were prospectively graded as normal/abnormal at each biopsy site.

RESULTS: Prostate cancer was detected in 122/901 (13.5%) of biopsy cores from 32 subjects, including 52/285 (18.2%) of targeted cores and 70/616 (11.4%) of systematic sextant cores. Prostate

cancer was detected in 19 subjects by targeted biopsy and 32 subjects by systematic sextant biopsy ($p < 0.001$). Among the 32 subjects with prostate cancer, targeted biopsy cores were 2.1 times more likely to detect the cancer as compared to systematic sextant cores ($p = 0.005$). Univariate analysis for gray scale, color Doppler and elastography demonstrated that each of these techniques was a significant predictor for the presence of malignancy ($p < 0.02$). Multivariate conditional logistic regression analysis demonstrated increased detection of prostate cancer in areas with abnormality on gray scale (OR = 4.4, $p = 0.25$), color Doppler (OR = 6.8, $p = 0.01$) and elastography (OR = 9.3, $p = 0.03$).

CONCLUSION: Sonographic findings on gray scale, color Doppler and elastography are correlated with the presence of prostate cancer. Both color Doppler and elastography provide additional significant information about the location of prostate cancer, beyond that which is provided by gray scale imaging. Nonetheless, a targeted biopsy approach based upon these imaging findings detected significantly fewer cancers as compared to systematic sextant biopsy.

Radiological Society of North America 91st Scientific Assembly and Annual Meeting, November 27th – 30th 2005, Chicago, USA

REAL-TIME ELASTOGRAPHY FOR PROSTATE CANCER DETECTION: PRELIMINARY EXPERIENCE.

Eva Pallwein¹, Leo Pallwein¹, Matthias Schurich¹, Wolfgang Horninger², Ferdinand Frauscher¹.
¹Radiology 2, ²Urology Departments, Medical University, Innsbruck, AUSTRIA.

Aims: For the first time, we used real-time elastography for the detection of prostate cancer.

Background: Since most solid tumors differ with regard with their consistency from the deriving tissue, elastography may offer a new tool for cancer detection.

Methods: We examined 15 patients (mean age: 56 ± 6.2 years; range: 46 - 71 years). All patients had the diagnosis of biopsy proven prostate cancer with a mean PSA of 4.6 (range, 1.4 - 16.1). All patients were scheduled for radical prostatectomy. We used a Voluson 730 (GE Ultrasound) US system with a 7.5 MHz transrectal transducer. The US examinations were performed by two investigators and interpreted in consensus. Cancer location and size was determined in the elastography mode. A single pathologist performed pathological classification of tumor localization, grade and stage. The real-time Elastography findings were compared with pathological findings.

Results: Radical prostatectomy was performed in all cases without major complications. All patients had a pT2 tumor on pathohistological examination. The Gleason score of our patients varied between 5 and 9. The tumor size varied from 0.2 to 3.5 cm (mean: 1.1 cm). Thirty-two foci of prostate cancer were present at pathologic evaluation. Multiple foci of cancer were found in 13 of the 15 glands (87%). Real-time elastography detected 28 of 32 cancer foci (sensitivity: 88%). Four sites were false-positive with no pathological abnormality. The patient by patient analysis demonstrated that real-time Elastography detected at least one cancer foci in each of the 15 patients. The limitations of our study were: a relatively small number of patients and the lack of data on inter- and intra-observer variability. The elastographic findings were evaluated for the presence of cancer only, and so we had no data about elastographic findings in BPH or other benign diseases.

Conclusions: Our data demonstrate that real-time elastography allows for detection of prostate cancer and estimation of tumor localization and size. Real-time elastography has shown to be capable for visualizing differences in tissue elasticity. Four sites with false positive findings on elastography and no pathohistological correlation were found in our study only. These findings were obtained in our first 5 patients (learning curve!). In summary, real-time elastography of the prostate is a unique imaging modality with a great potential for the detection of prostate cancer.

Fourth International Conference on the Ultrasonic Measurement and Imaging of Tissue Elasticity, October 16th – 19th 2005, Austin, Texas

SONOELASTOGRAPHY OF THE TESTICLES: PRELIMINARY RESULTS IN THE DIAGNOSIS OF DIFFERENT PATHOLOGICAL PROCESSES.

L Pallwein¹, E Pallwein¹, M Schurich¹, V Fischbach¹, H Steiner², F Frauscher¹.

¹Radiology, ²Urology Departments, Medical University, Innsbruck, AUSTRIA.

Aims: To assess the value of sonoelastography in the differential diagnosis of inflammatory and neoplastic disease of the testicles.

Background: In a patient with acute scrotal pain and swelling, the differentiation of neoplastic from inflammatory processes in the testicles can be difficult and usually a biopsy is required. Elastography of the testicles may improve the detection of areas with increased stiffness which are suspicious for neoplastic changes and, therefore, may also improve the differentiation between neoplastic and inflammatory processes.

Methods: In 15 patients suffering from scrotal pain and swelling, a routine US examination (B-mode and color Doppler US) was performed (Acuson Sequoia, Mountainview, Ca, USA). All patients underwent an additional qualitative measurement of tissue elasticity by using sonoelastography (Hitachi EUB-8500). These exams were performed by a different urologist, who was blinded to the results of routine sonography. The stiffness of the lesion was displayed from red (soft) to blue (hard). Hard lesions were considered as malignant. The diagnostic outcome of the two examinations was compared in each patient.

Results: In 7 patients, routine US was able to detect testicular masses of different size, which were histologically proven to be neoplastic lesions of different types (germ cell tumor, seminoma, teratoma, mixed tumors and sarcoma of the tunica albuginea in one case). Elastography was able to detect all these lesions and enabled the detection of two additional lesions that were not well circumscribed in a patient suspected to have tumor recurrence in a single testis. Elastography was also able to differentiate between inflammatory changes and testicular swelling in a patient suspected of diffuse lymphomatous infiltration based on the differences in tissue stiffness. Inflammatory processes of the testicles showed normal to decreased tissue stiffness in the suspected areas.

Conclusions: Our preliminary findings showed that in patients with diffuse scrotal swelling and pain, the sonoelastography improved the detection of testicular masses and allow the differentiation of inflammatory changes from other pathological processes based on the differences in tissue elasticity.

*Fourth International Conference on the Ultrasonic Measurement and Imaging of Tissue Elasticity,
October 16th – 19th 2005, Austin, Texas*